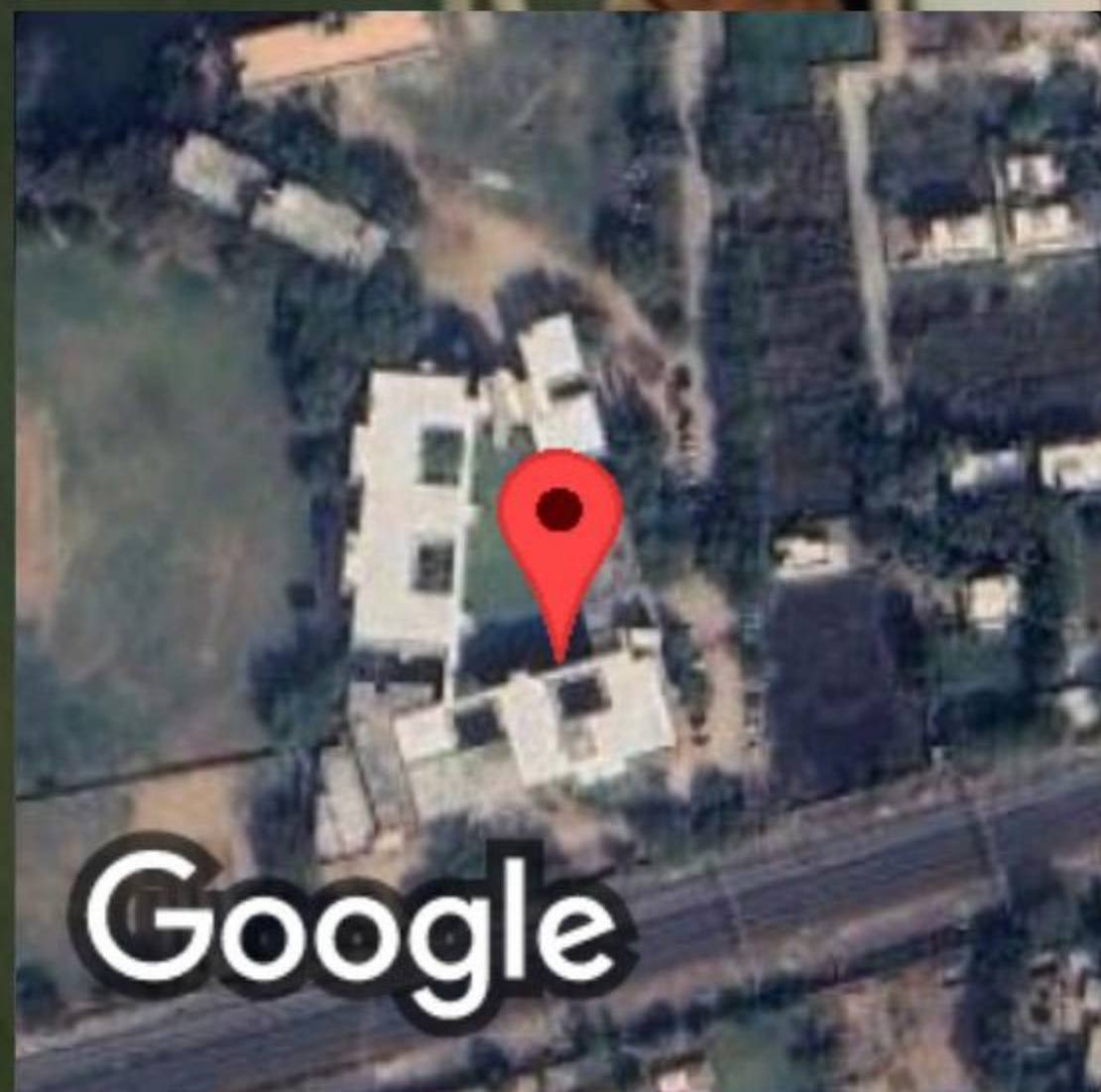

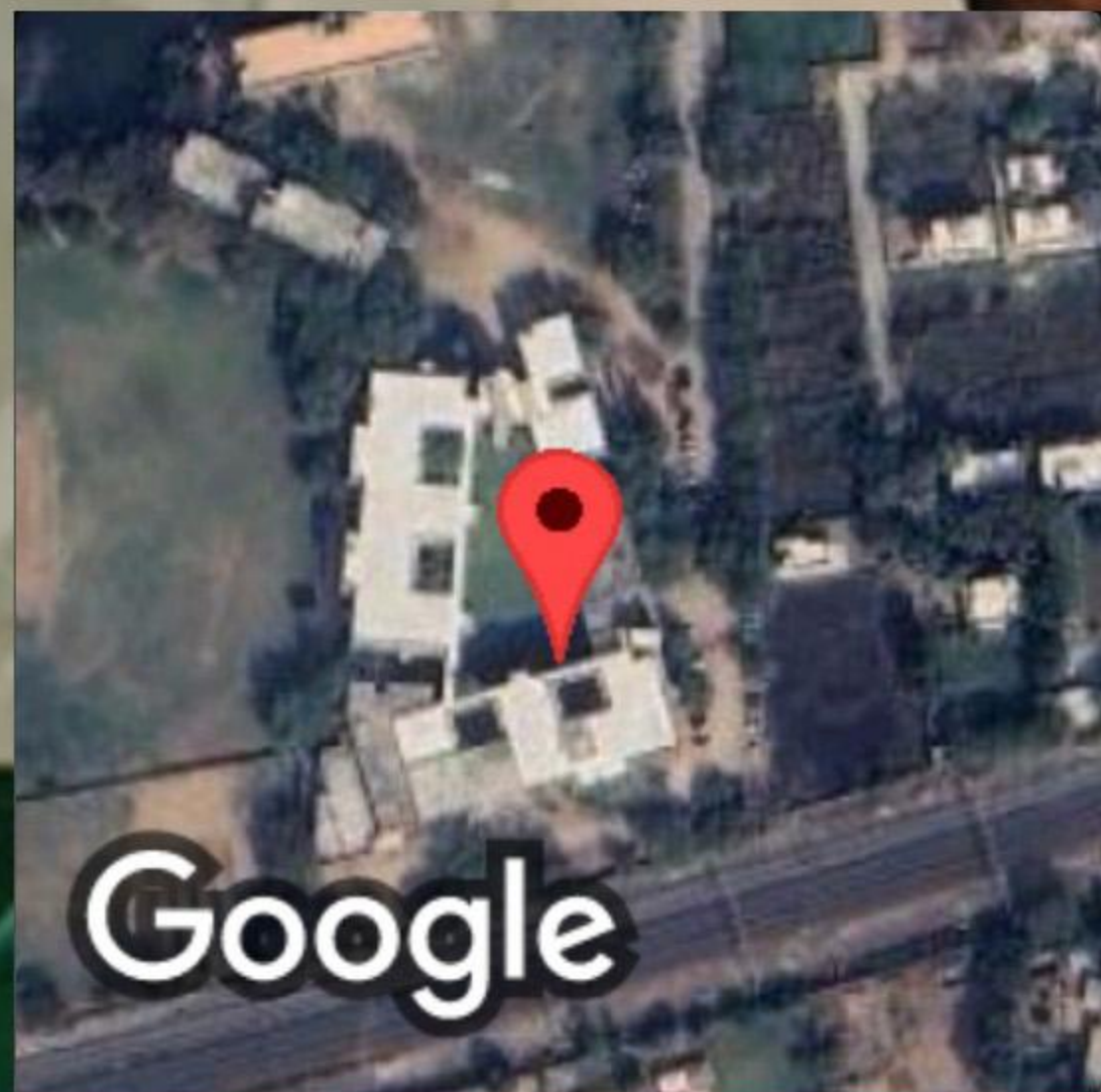
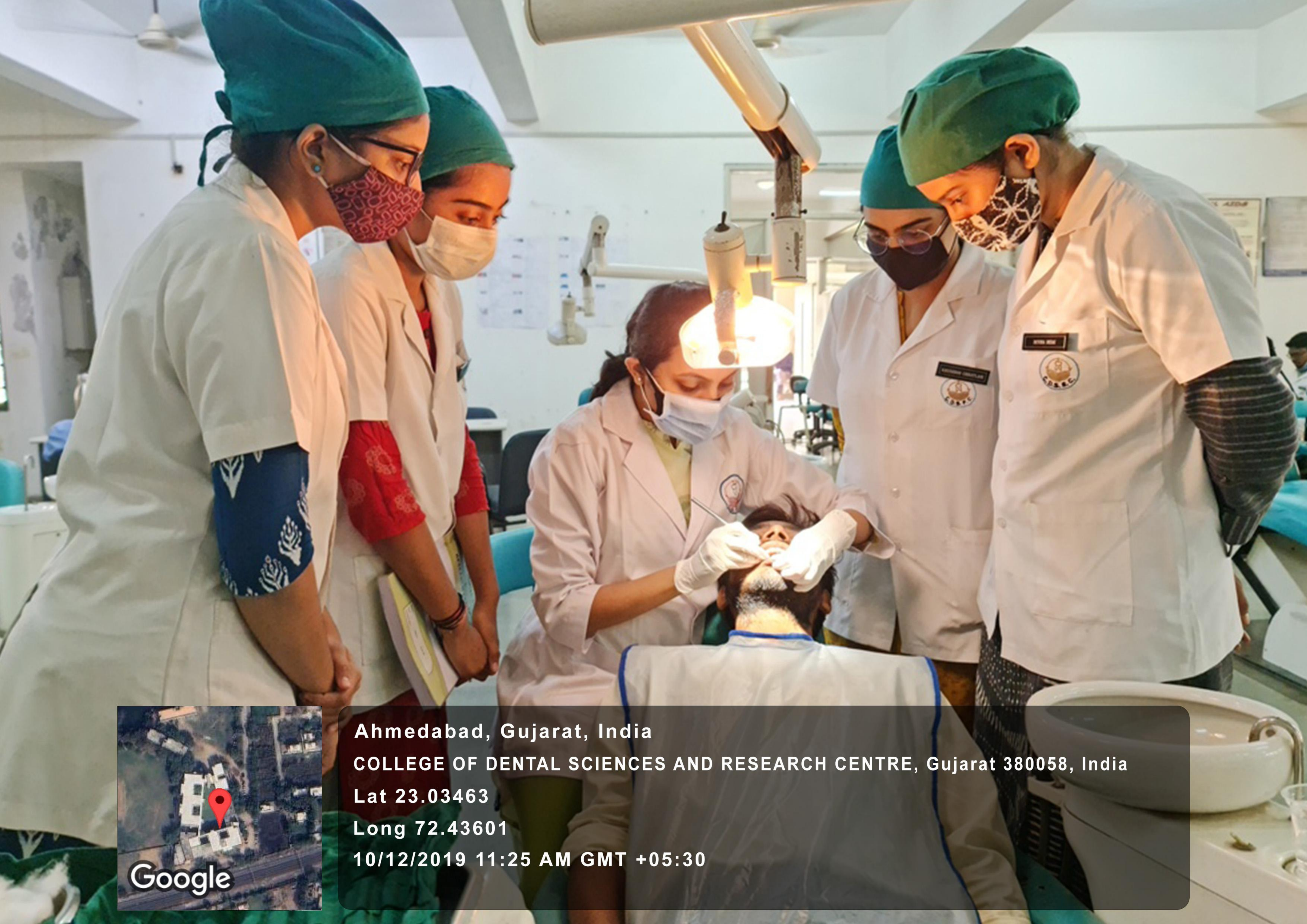Ahmedabad, Gujarat, India

COLLEGE OF DENTAL SCIENCES AND RESEARCH CENTRE, Gujarat 380058, India

Lat 23.03463

Long 72.43601

19/08/2019 11:15 AM GMT +05:30



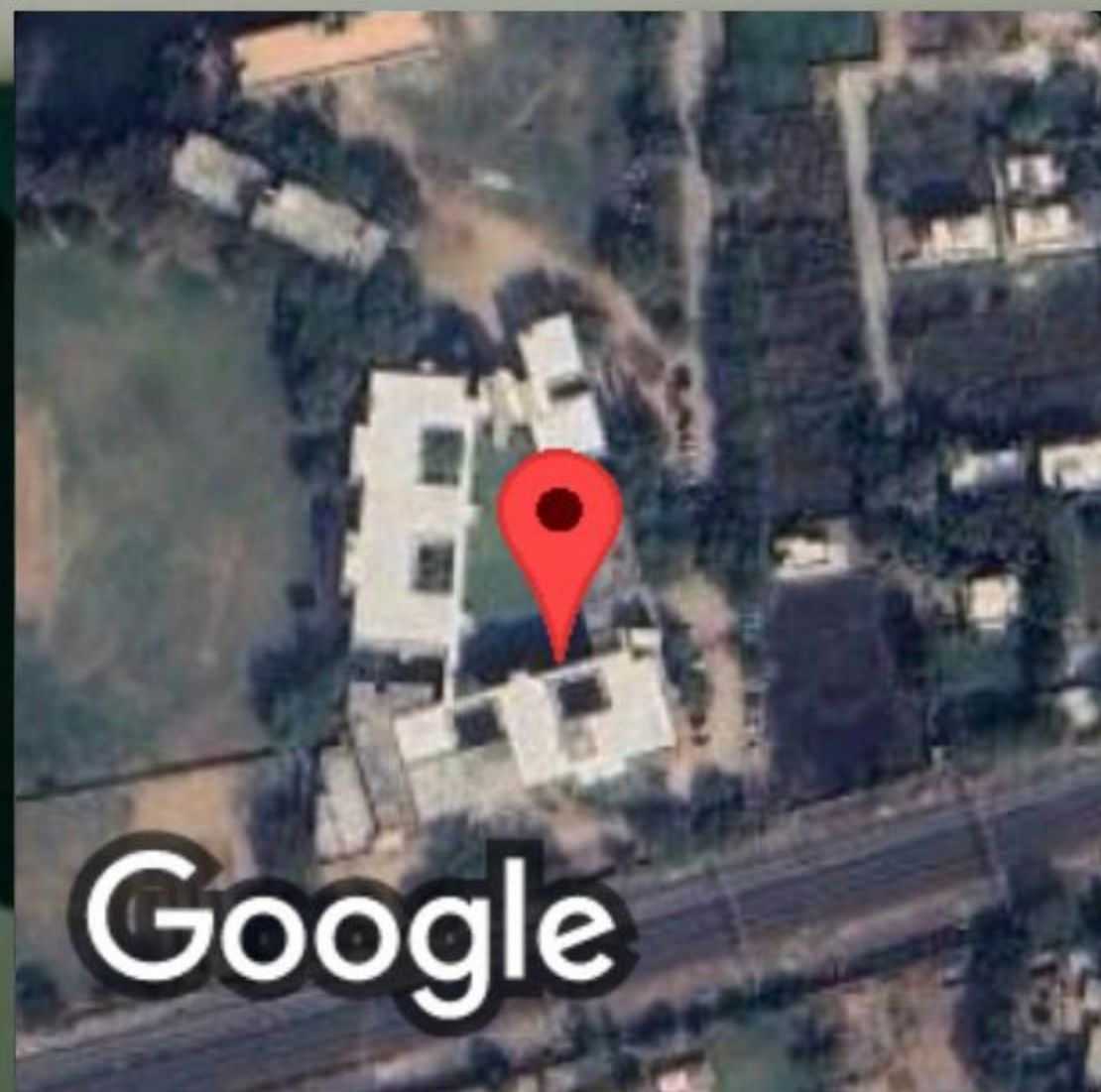
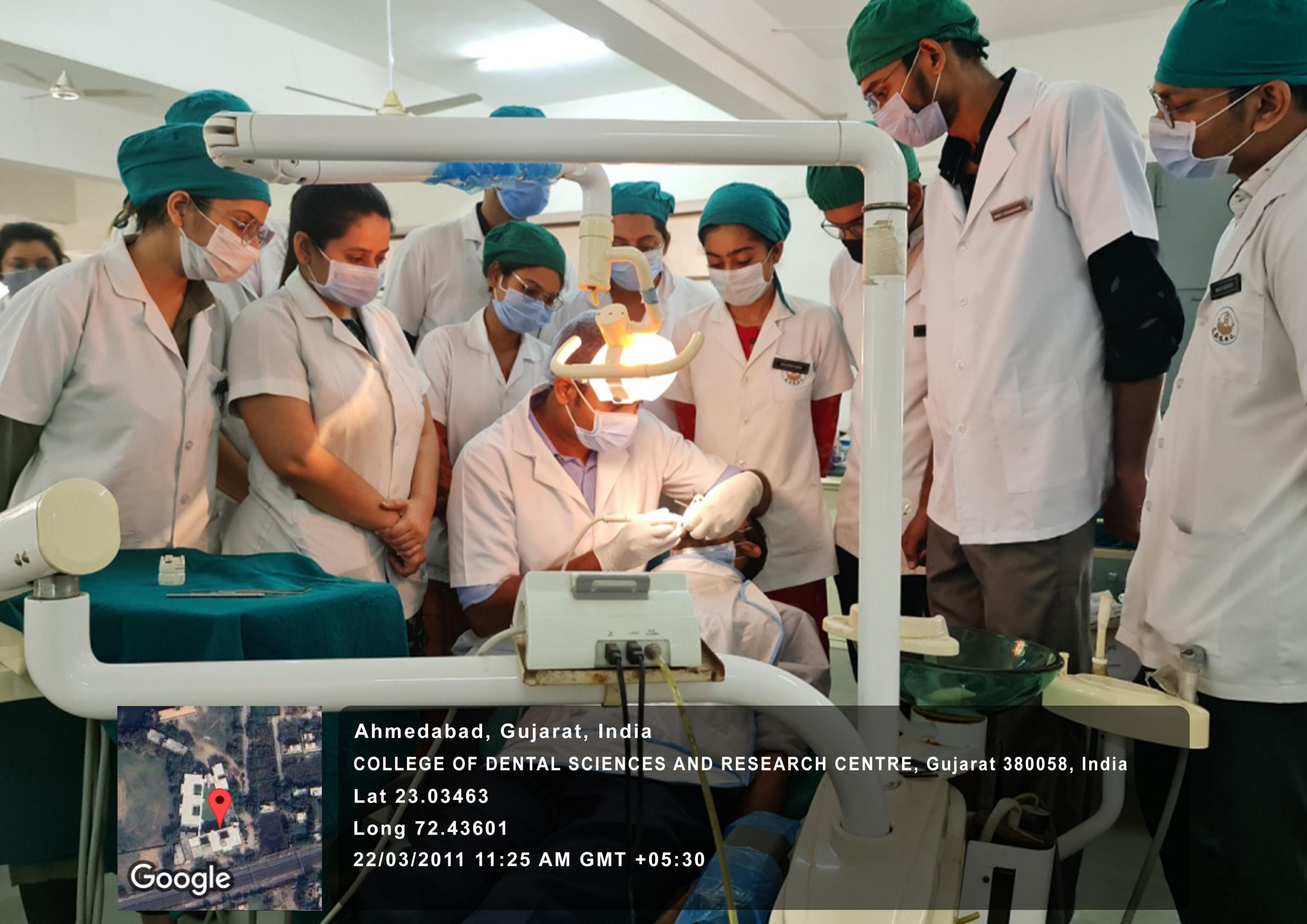Ahmedabad, Gujarat, India

COLLEGE OF DENTAL SCIENCES AND RESEARCH CENTRE, Gujarat 380058, India

Lat 23.03463

Long 72.43601

10/12/2019 11:25 AM GMT +05:30



Ahmedabad, Gujarat, India

COLLEGE OF DENTAL SCIENCES AND RESEARCH CENTRE, Gujarat 380058, India

Lat 23.03463

Long 72.43601

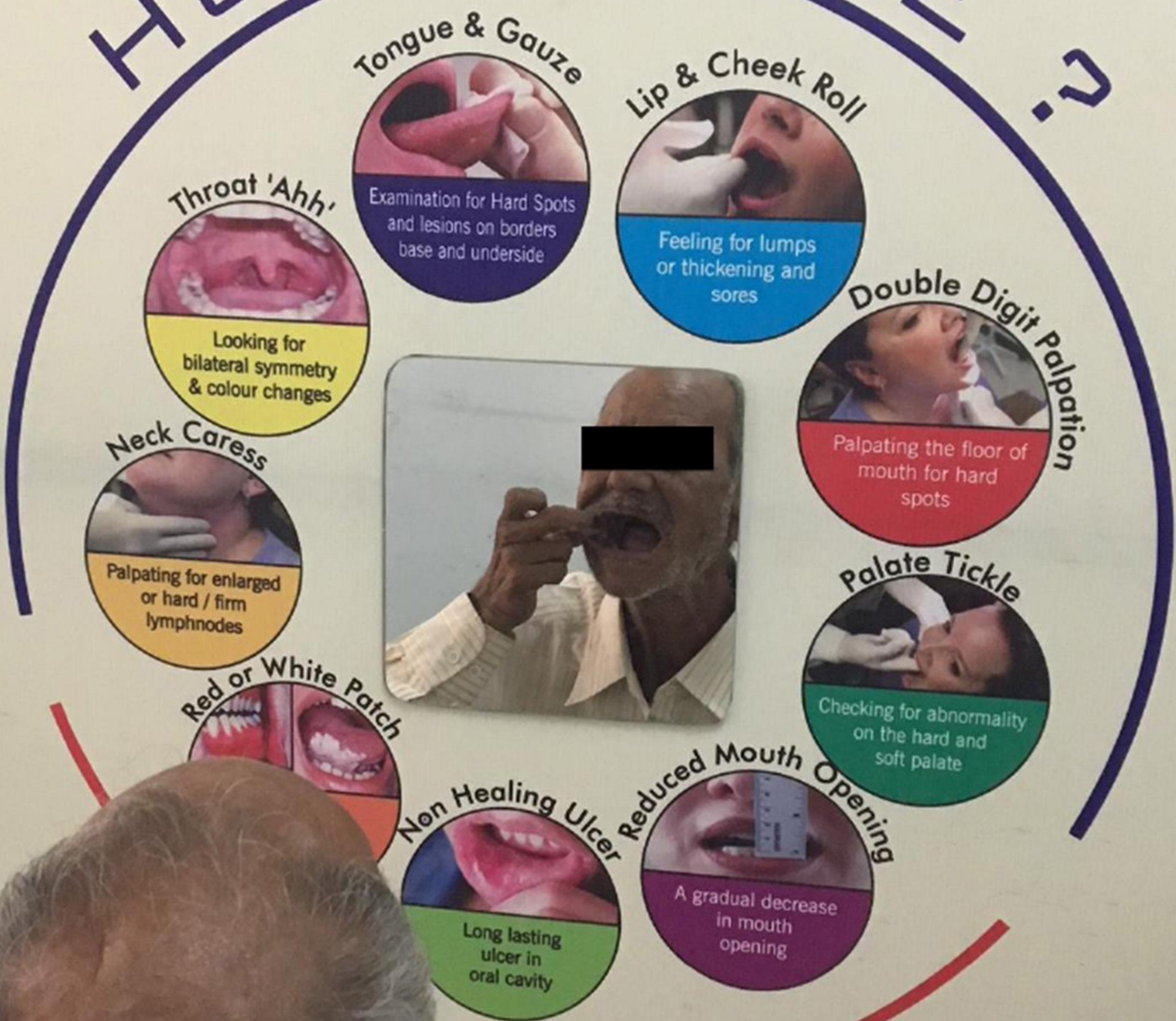
22/03/2011 11:25 AM GMT +05:30

# SELF ASSESSMENT FOR ORAL CANCER



EARLY STAGE ORAL CANCER IS OFTEN PAINLESS & GOES UNDETECTED

## HOW TO SEE ?



## HOW TO SEE ?

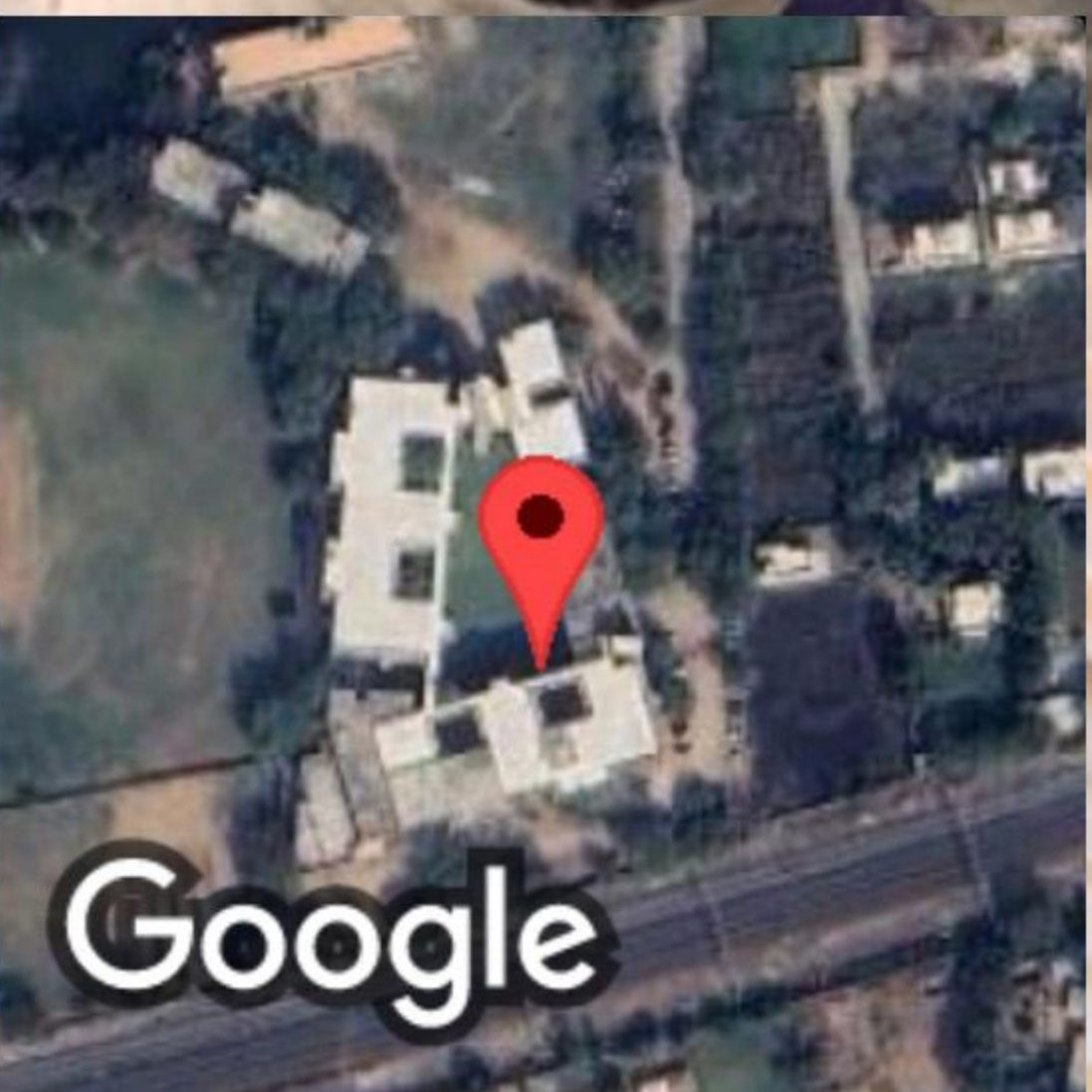
Ahmedabad, Gujarat, India

COLLEGE OF DENTAL SCIENCES AND RESEARCH CENTRE, Gujarat 380058, India

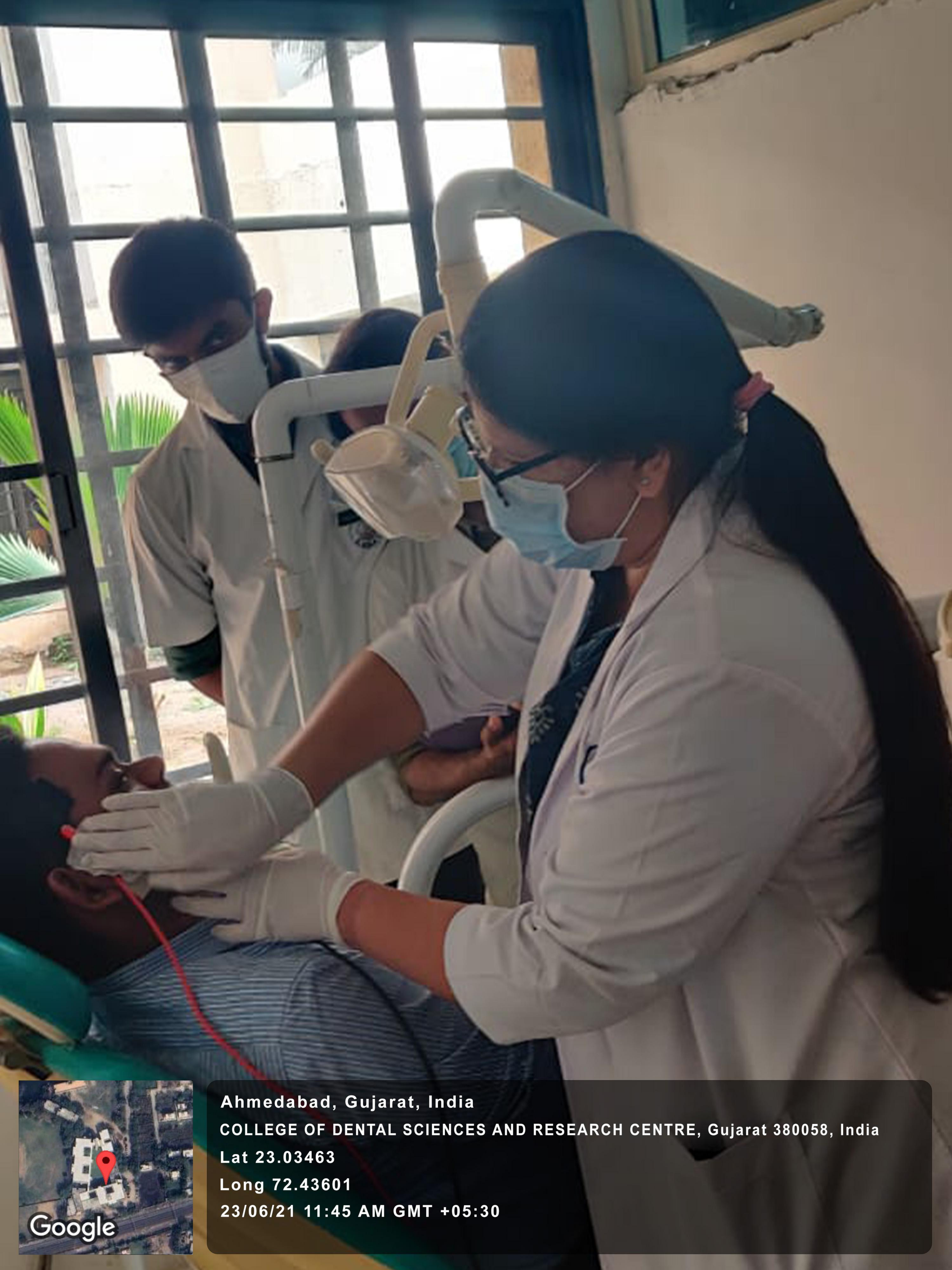
Lat 23.03463

Long 72.43601

28/01/21 11:11 AM GMT +05:30



Google



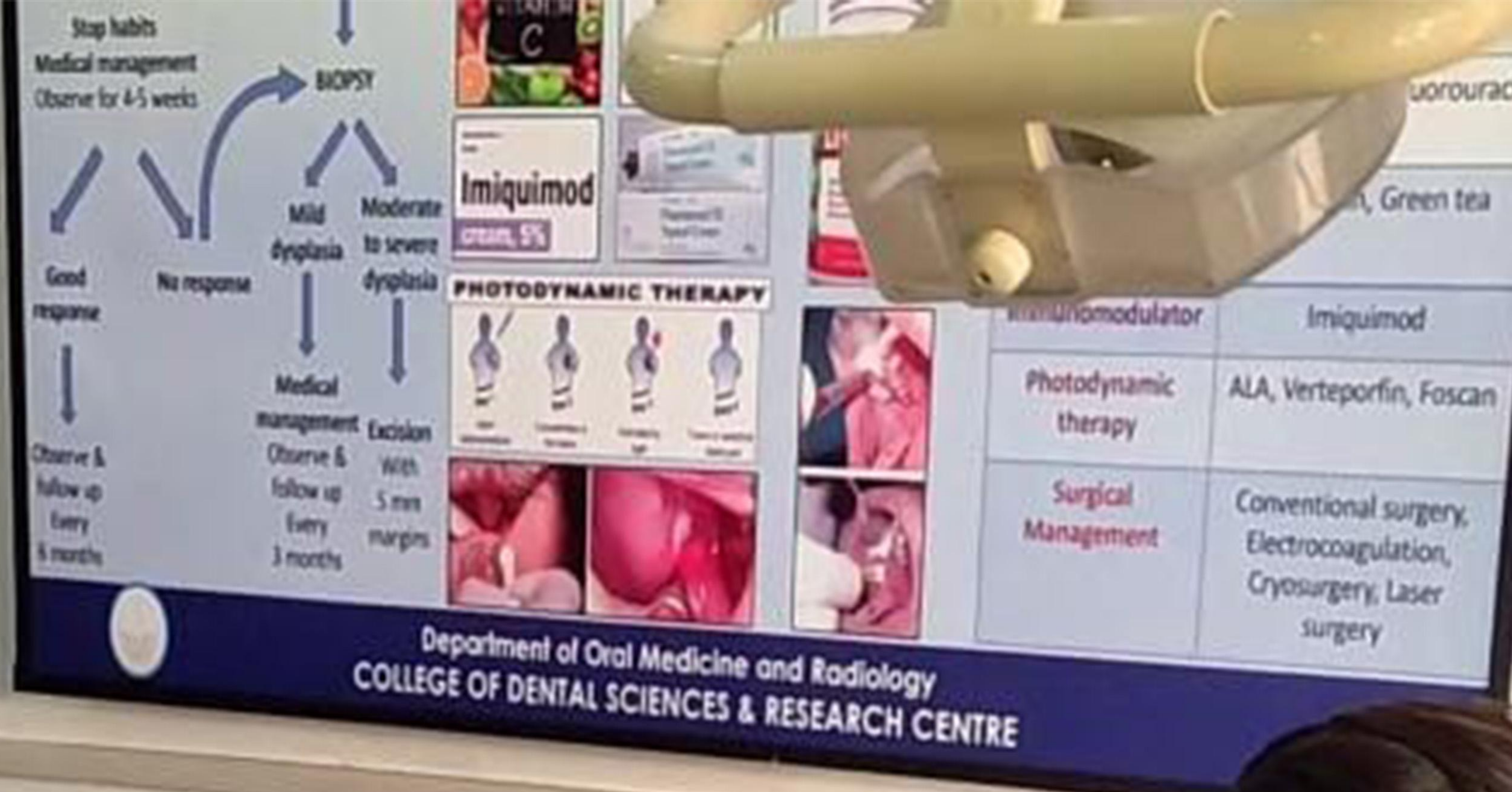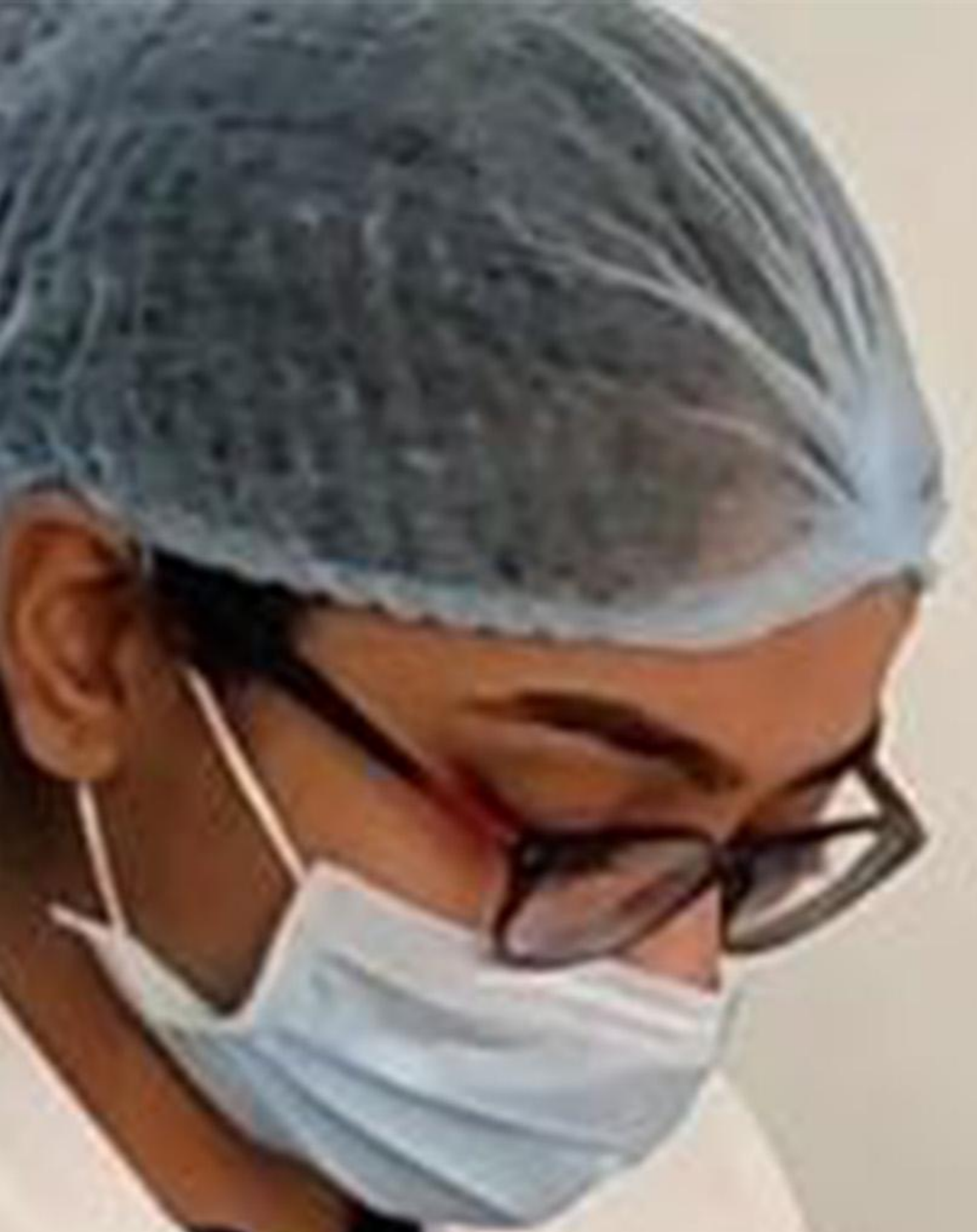Ahmedabad, Gujarat, India

COLLEGE OF DENTAL SCIENCES AND RESEARCH CENTRE, Gujarat 380058, India

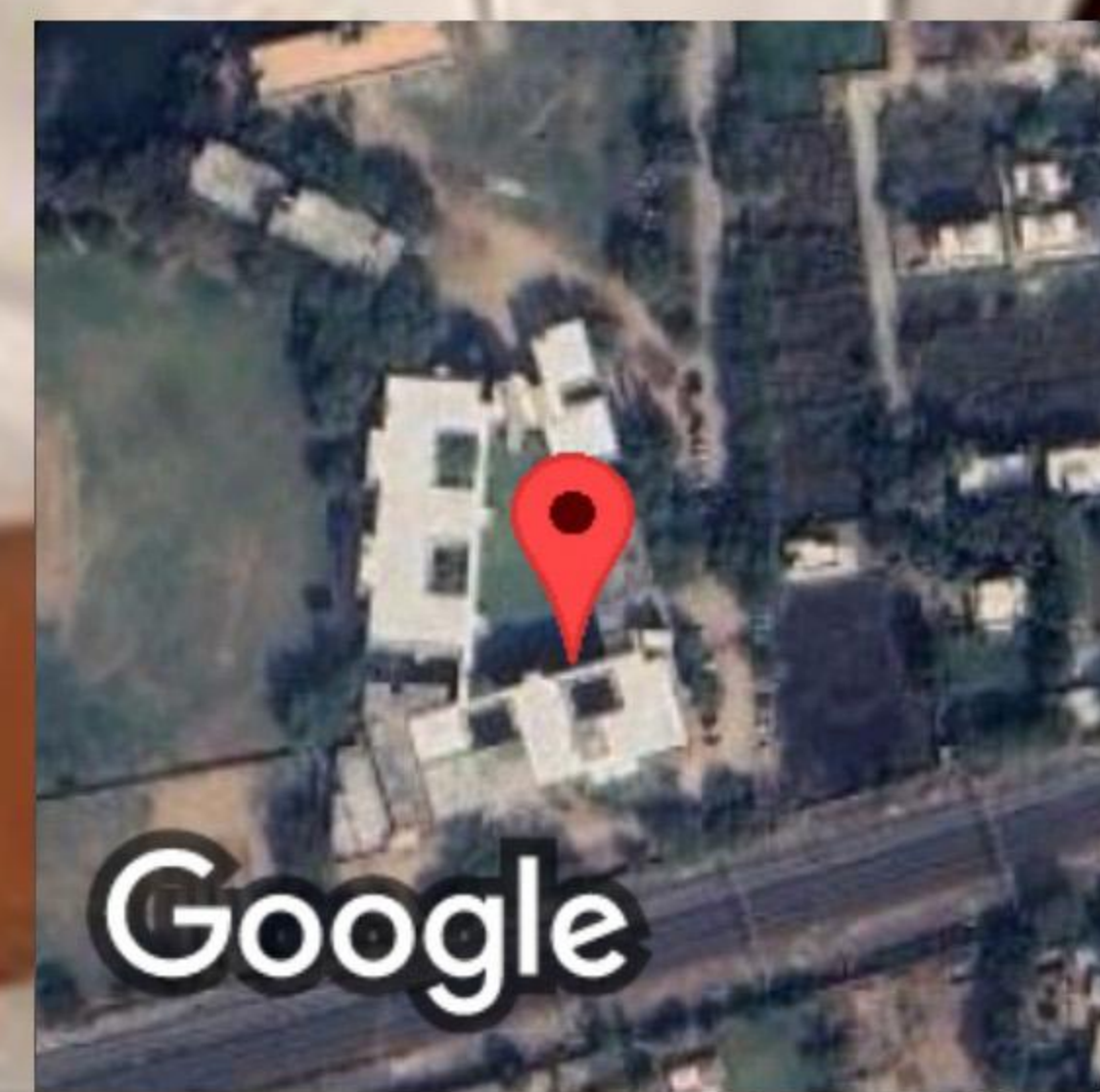
Lat 23.03463

Long 72.43601

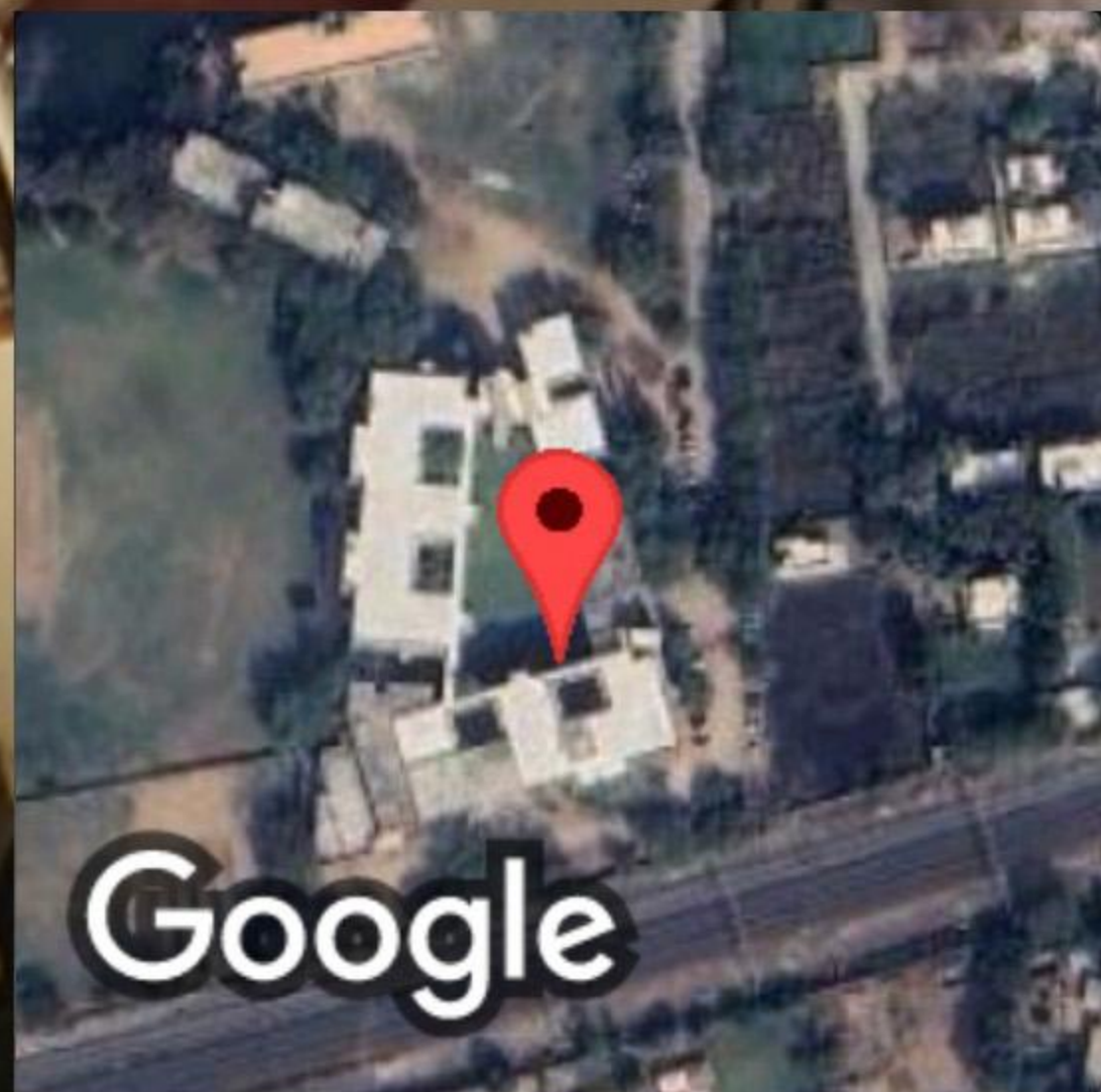
23/06/21 11:45 AM GMT +05:30



ANALYSIS OF  
DISORDERS



Ahmedabad, Gujarat, India  
 COLLEGE OF DENTAL SCIENCES AND RESEARCH CENTRE, Gujarat 380058, India  
 Lat 23.03463  
 Long 72.43601  
 21/10/2021 11:40 AM GMT +05:30



**Ahmedabad, Gujarat, India**

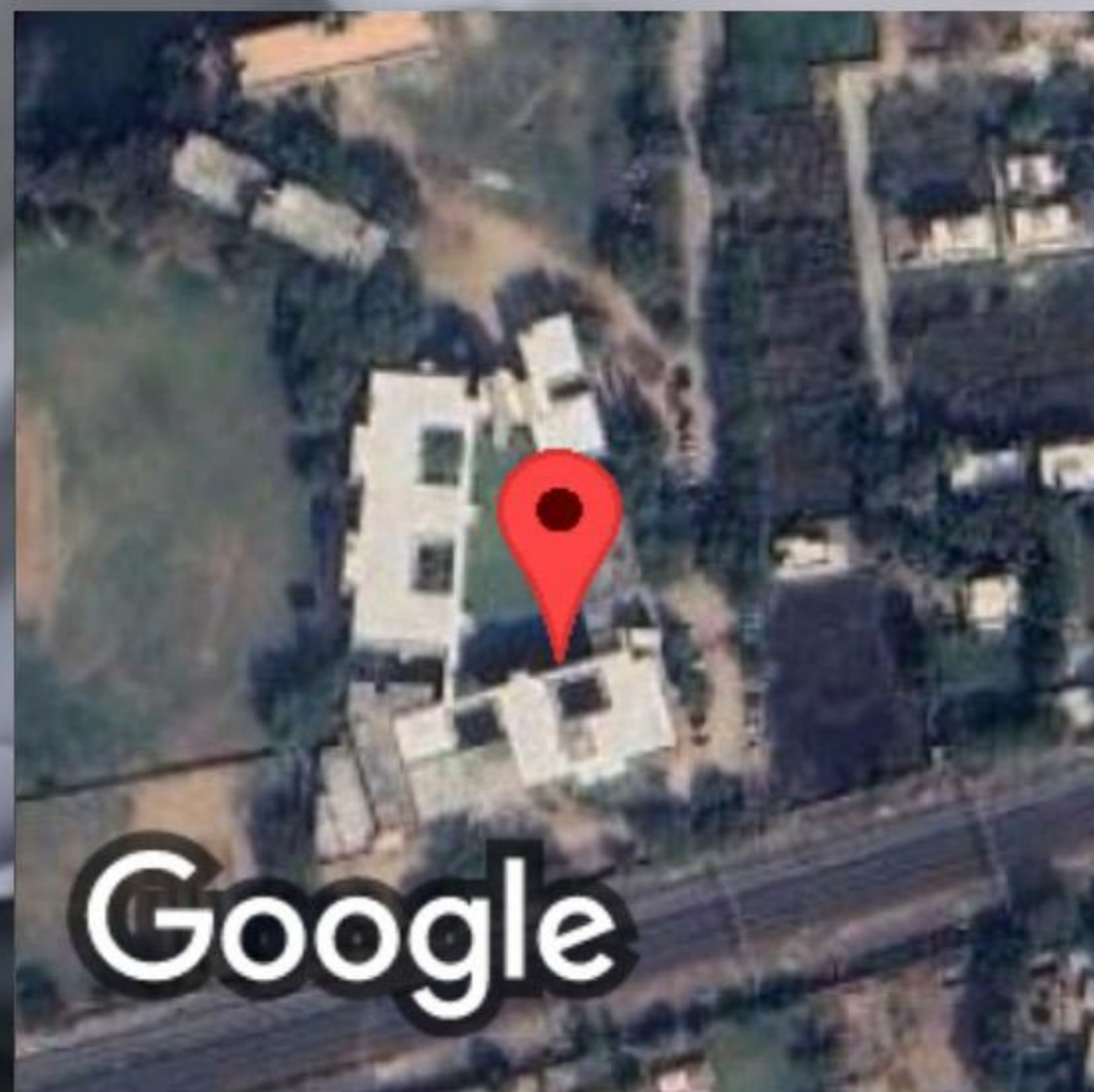
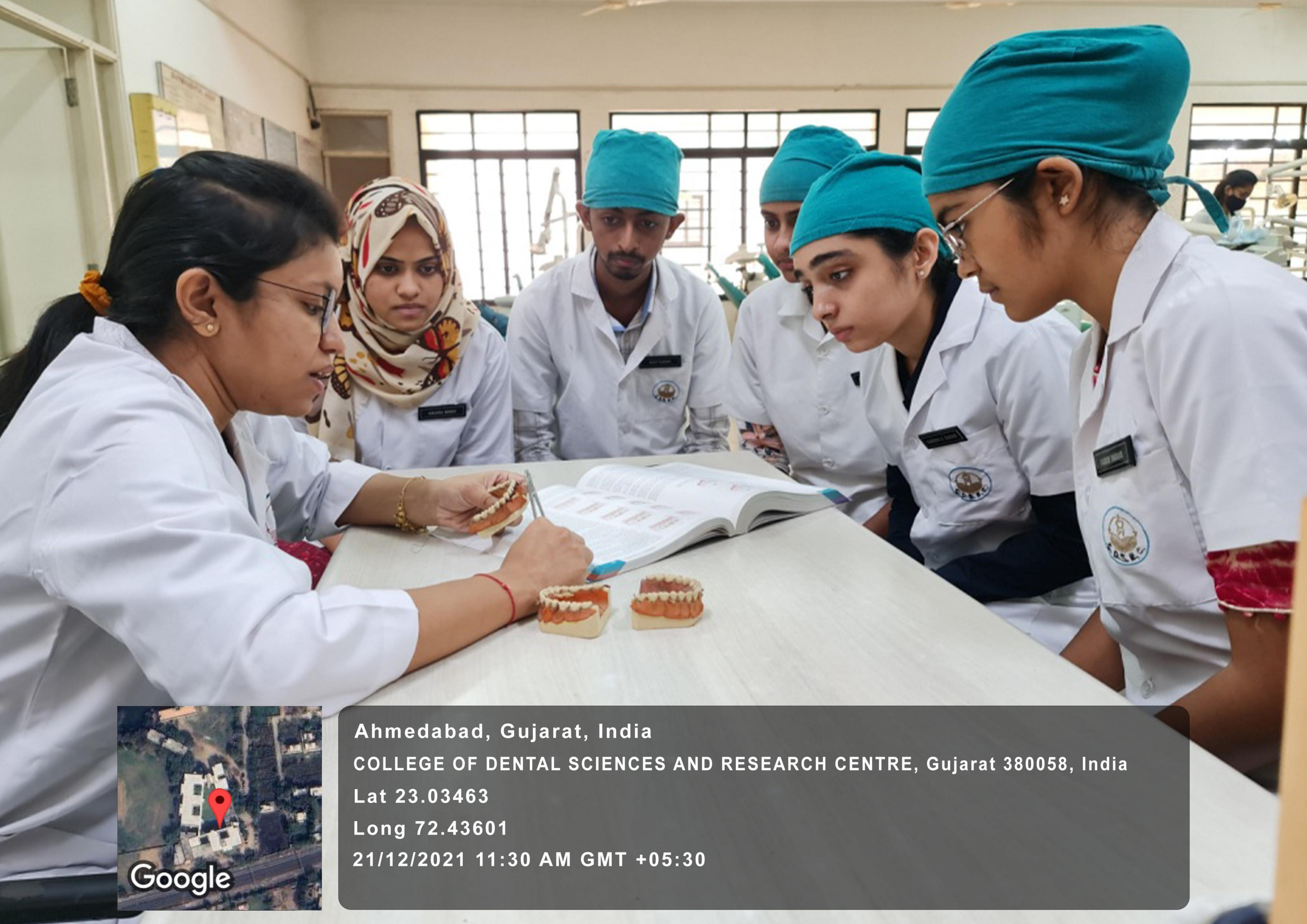**COLLEGE OF DENTAL SCIENCES AND RESEARCH CENTRE, Gujarat 380058, India**

**Lat 23.03463**

**Long 72.43601**

**24/08/2021 11:50 AM GMT +05:30**





Ahmedabad, Gujarat, India

COLLEGE OF DENTAL SCIENCES AND RESEARCH CENTRE, Gujarat 380058, India

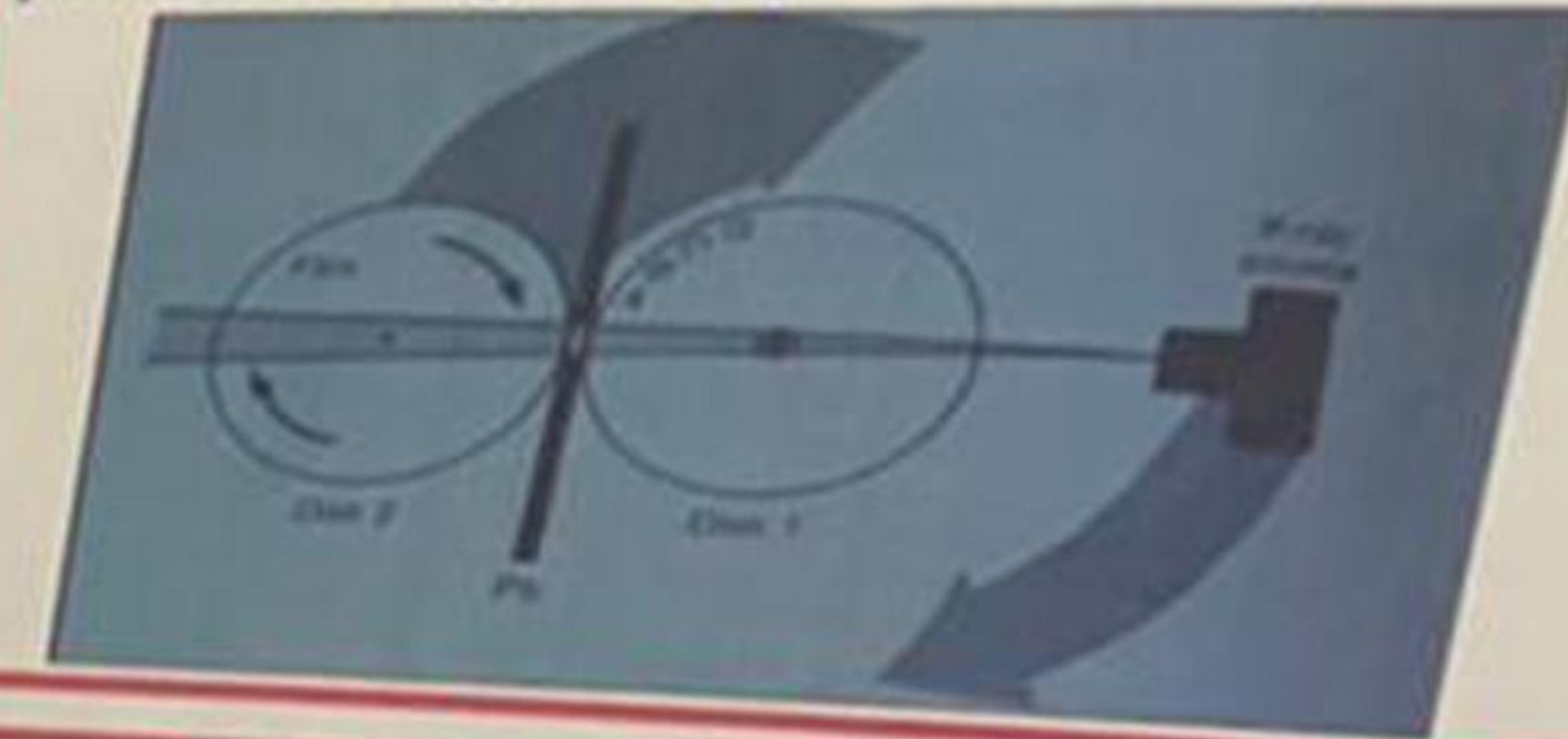
Lat 23.03463

Long 72.43601

21/12/2021 11:30 AM GMT +05:30



image receptor, around a center of rotation locate patient, with same speed and same direction will produce an image called panoramic image.



## INDICATION

- Routine diagnostic survey.
- Patients unable to open their mouth.
- Severe gag sensation.
- Evaluation of third molars.
- Evaluation of pathology like cyst or tumors.
- For detection of fracture of jaw.

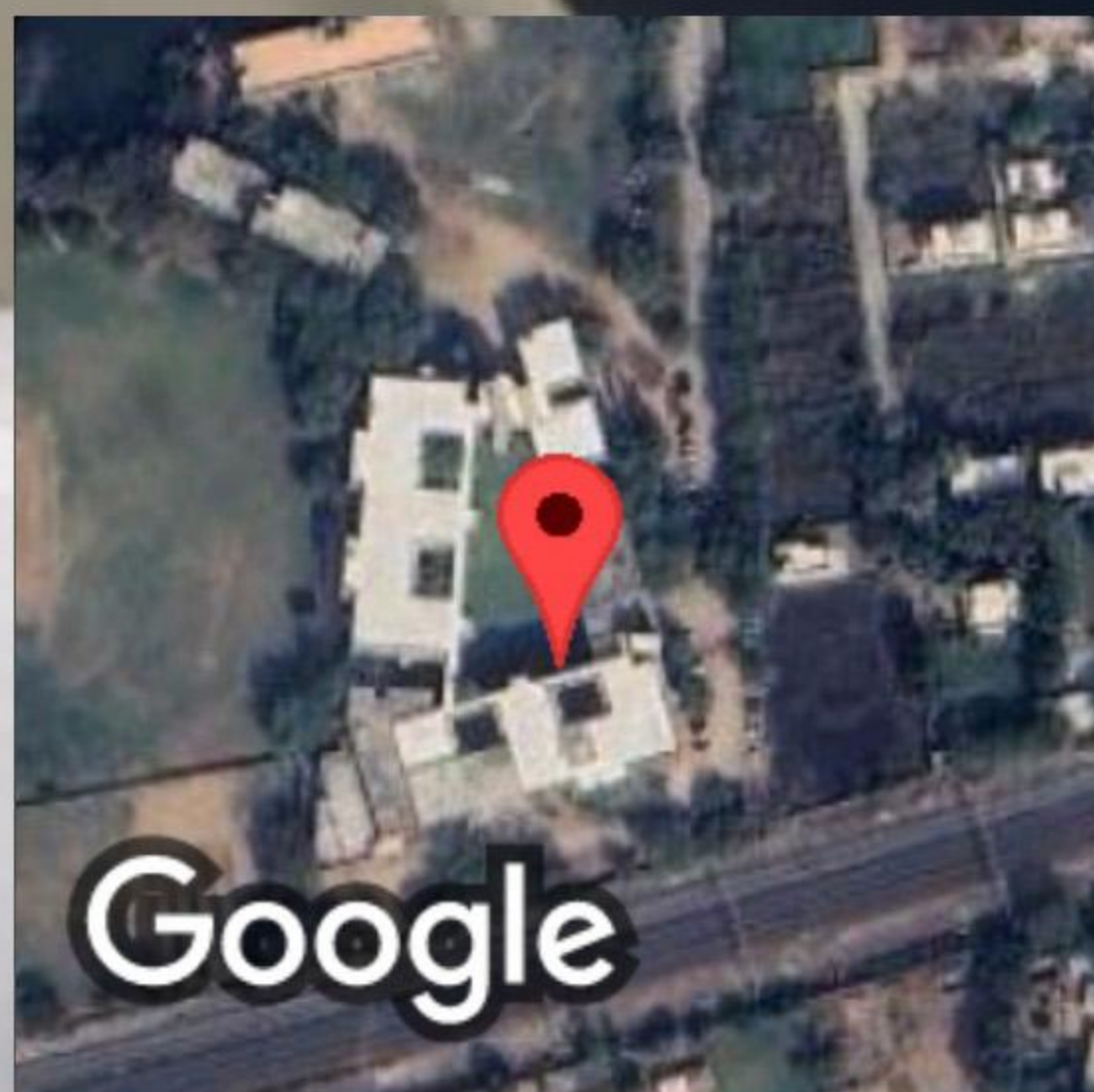
t areas. .

## BIT POSIT

too low

Grum

ON : Chin th



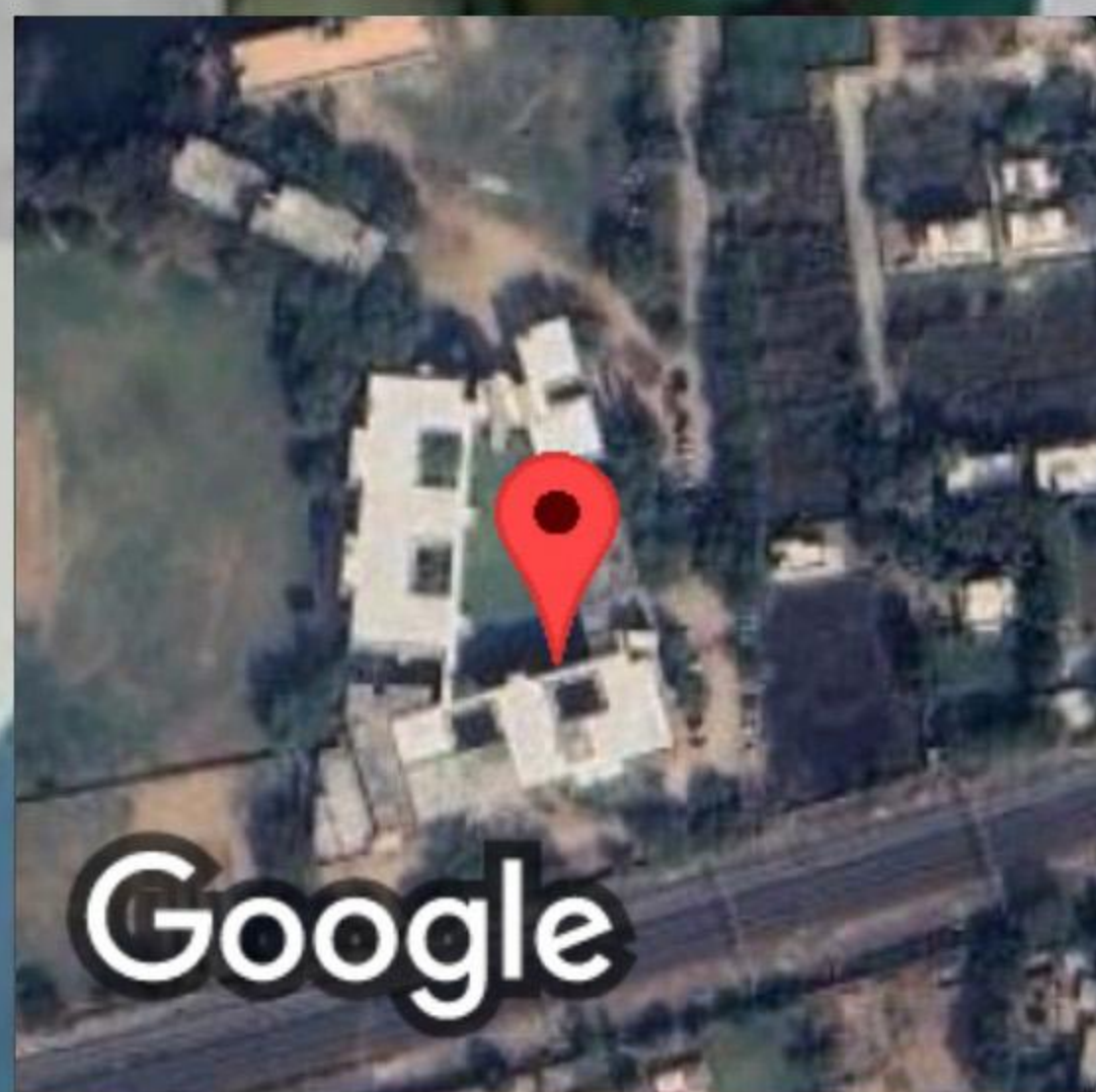
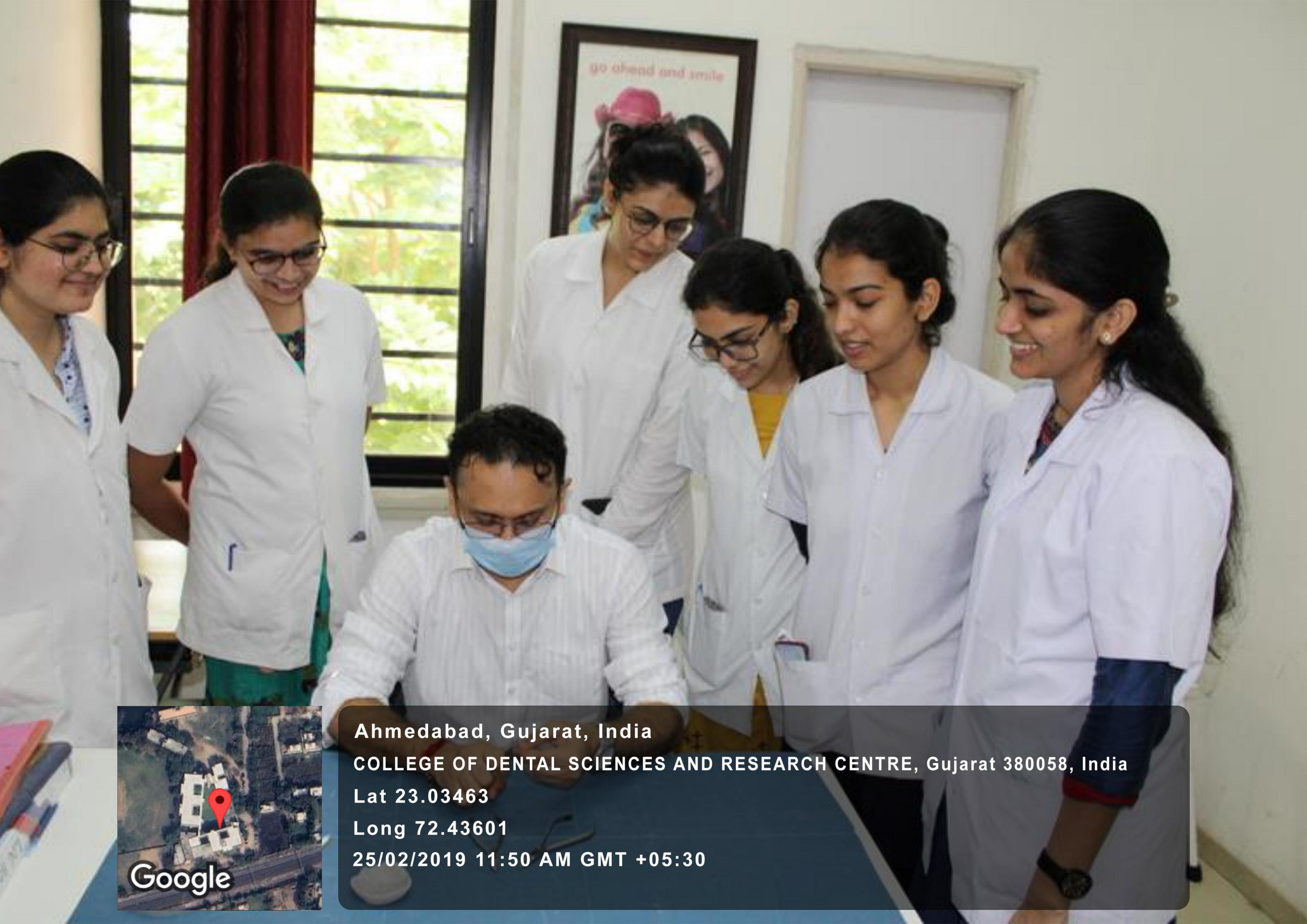Ahmedabad, Gujarat, India

COLLEGE OF DENTAL SCIENCES AND RESEARCH CENTRE, Gujarat 380058, India

Lat 23.03463

Long 72.43601

24/06/2019 10:10 AM GMT +05:30



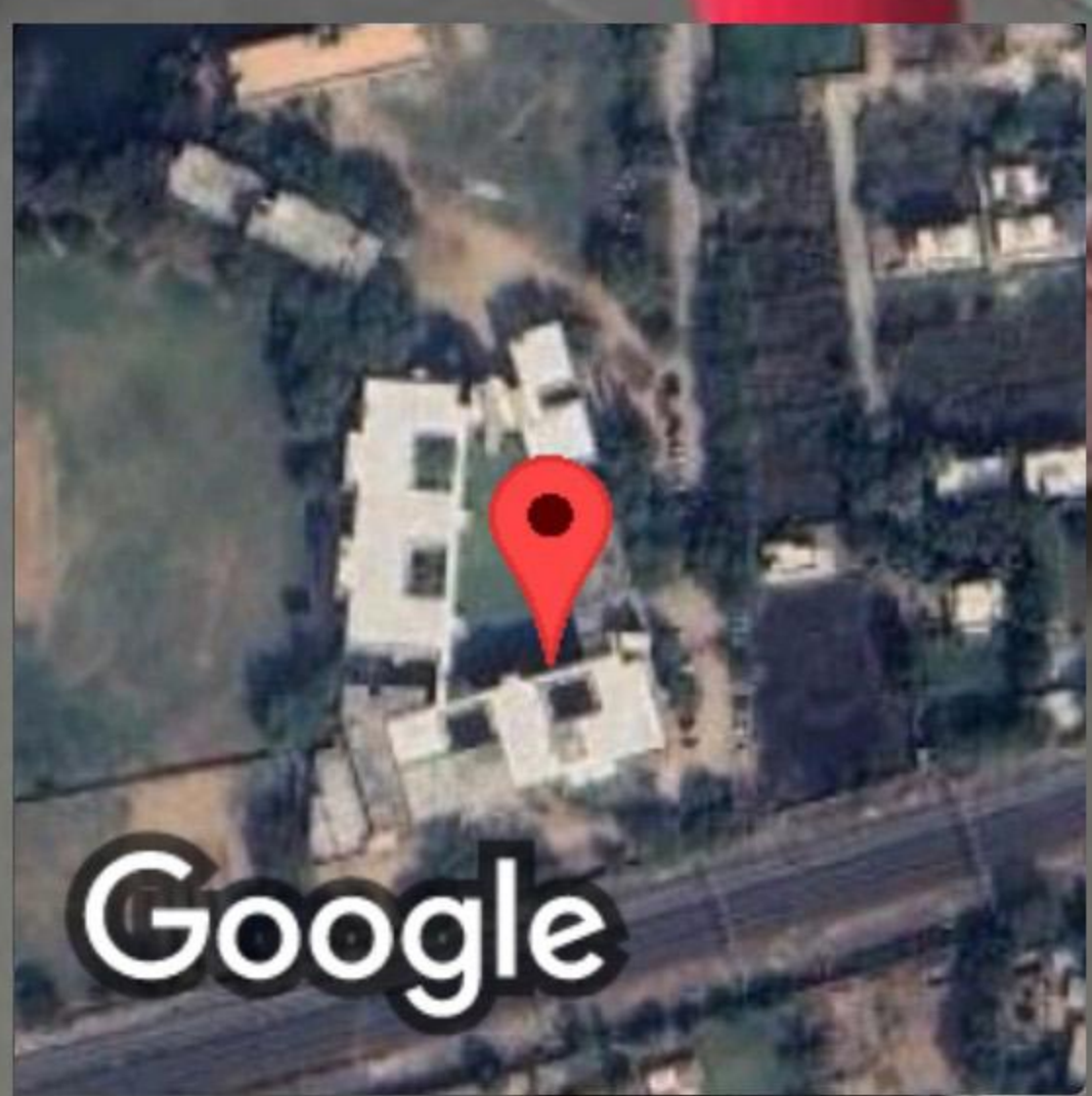
Ahmedabad, Gujarat, India

COLLEGE OF DENTAL SCIENCES AND RESEARCH CENTRE, Gujarat 380058, India

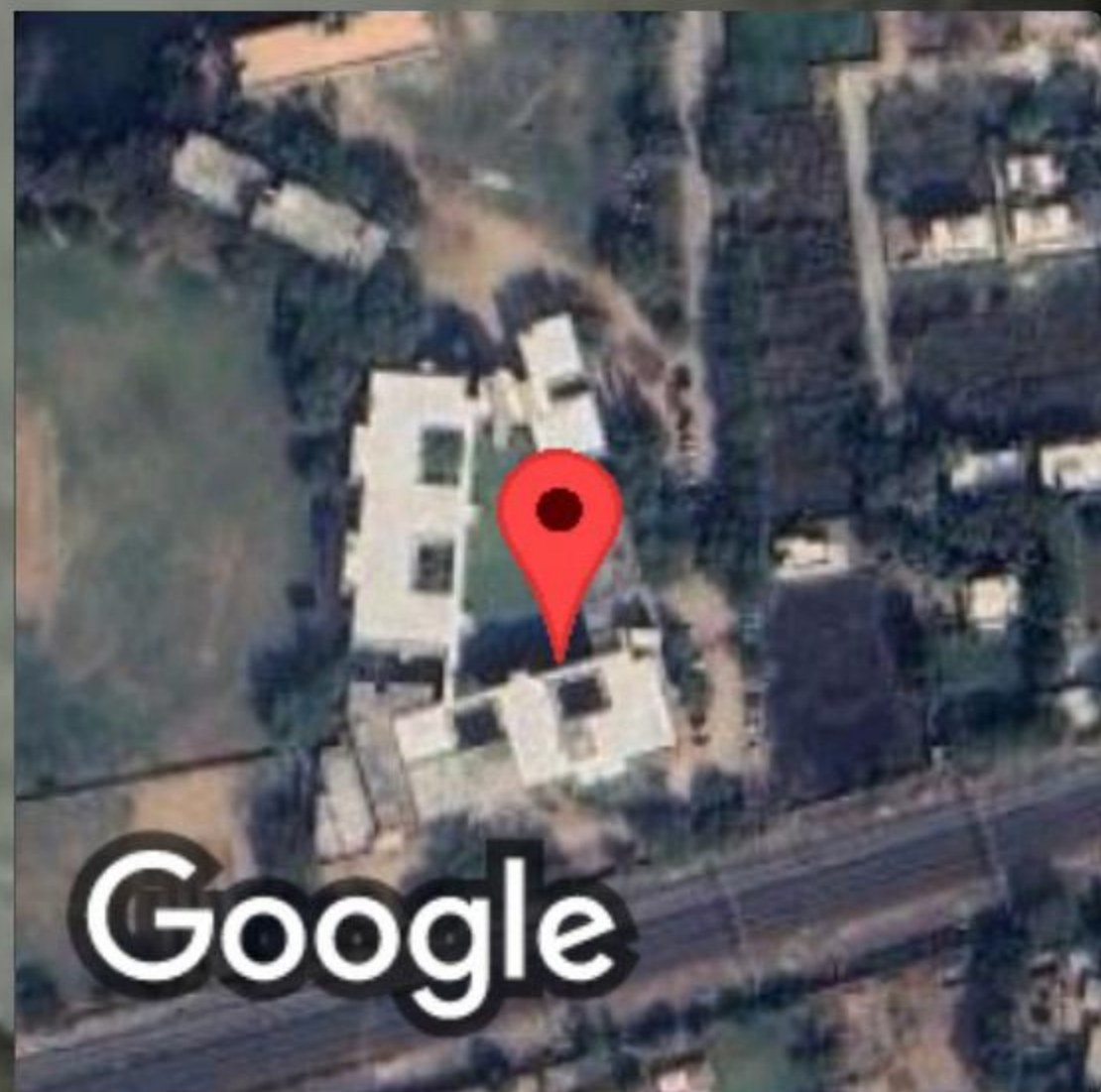
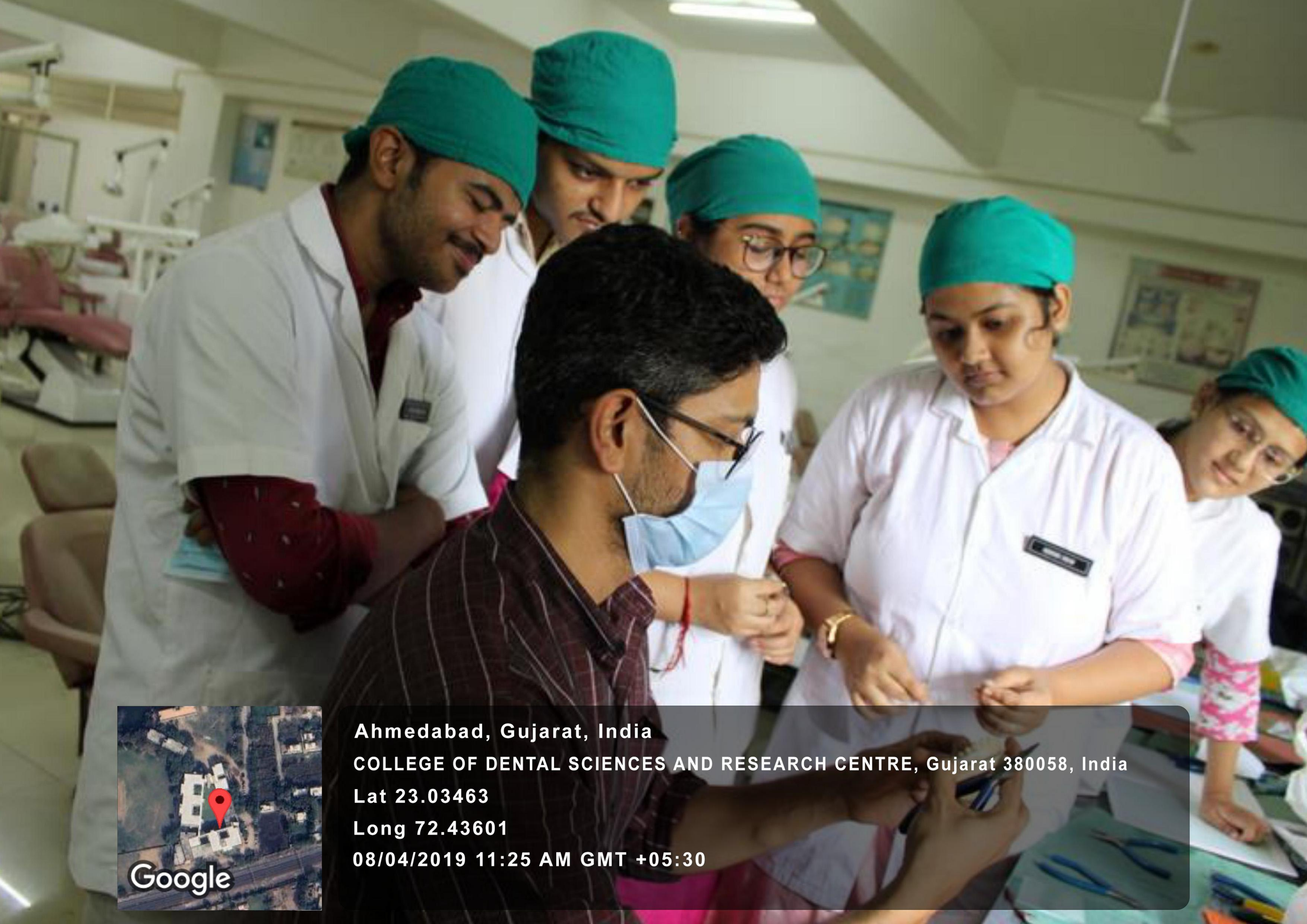Lat 23.03463

Long 72.43601

25/02/2019 11:50 AM GMT +05:30



Ahmedabad, Gujarat, India  
 COLLEGE OF DENTAL SCIENCES AND RESEARCH CENTRE, Gujarat 380058, India  
 Lat 23.03463  
 Long 72.43601  
 10/04/19 11:15 AM GMT +05:30



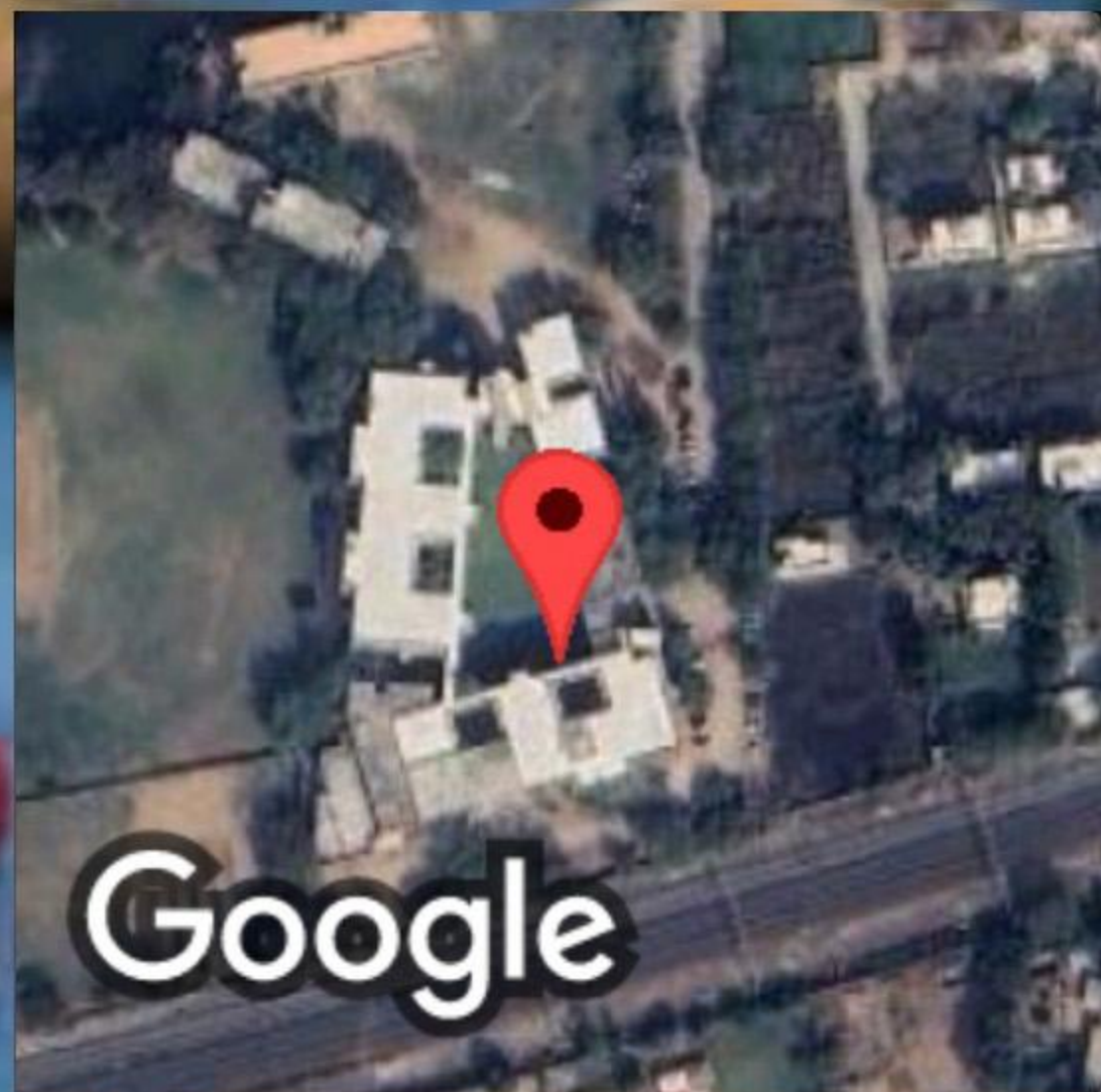
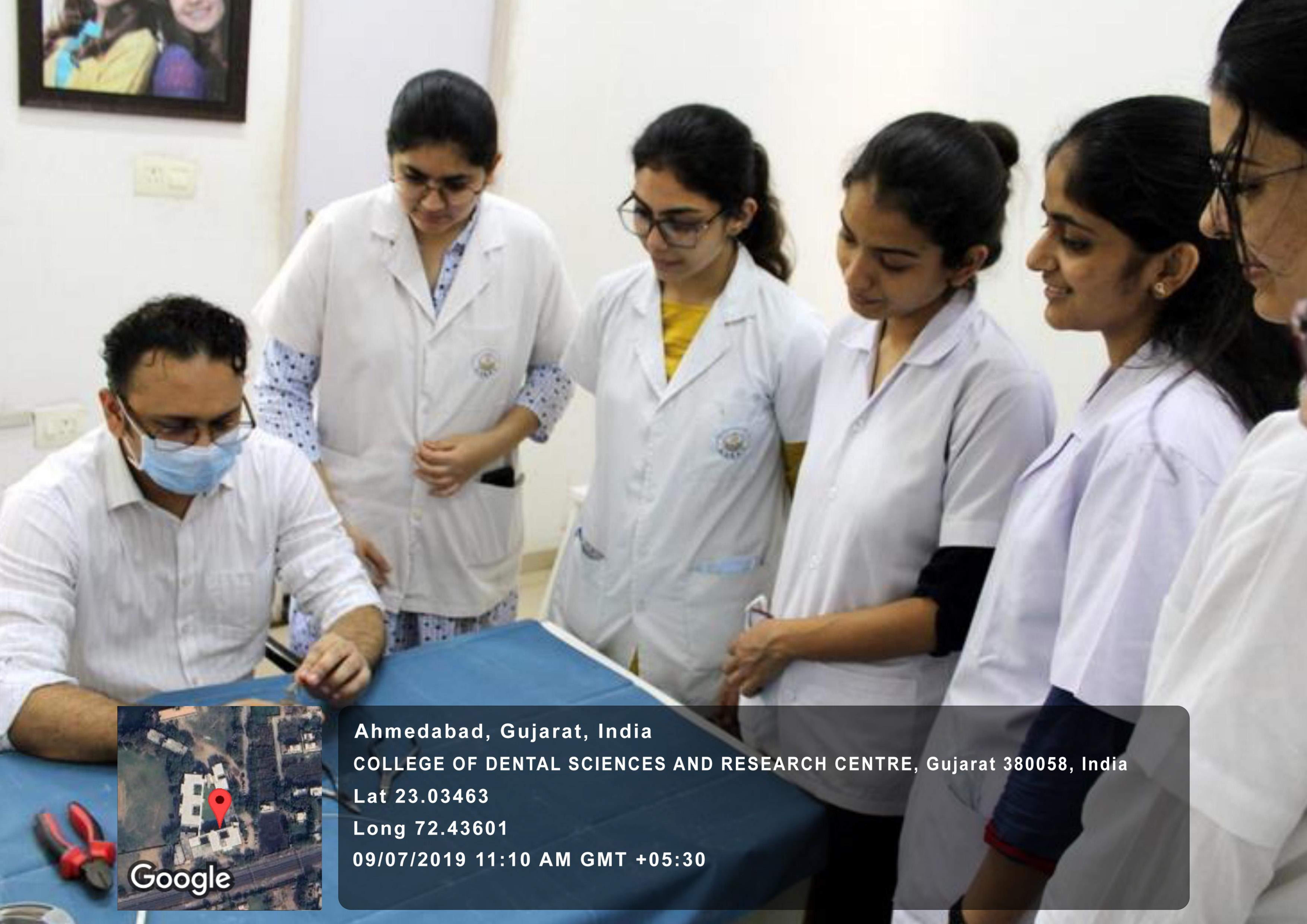Ahmedabad, Gujarat, India

COLLEGE OF DENTAL SCIENCES AND RESEARCH CENTRE, Gujarat 380058, India

Lat 23.03463

Long 72.43601

08/04/2019 11:25 AM GMT +05:30



**Ahmedabad, Gujarat, India**

**COLLEGE OF DENTAL SCIENCES AND RESEARCH CENTRE, Gujarat 380058, India**

**Lat 23.03463**

**Long 72.43601**

**09/07/2019 11:10 AM GMT +05:30**



PRIMA

**BIOMECHANICAL PREPARATION**

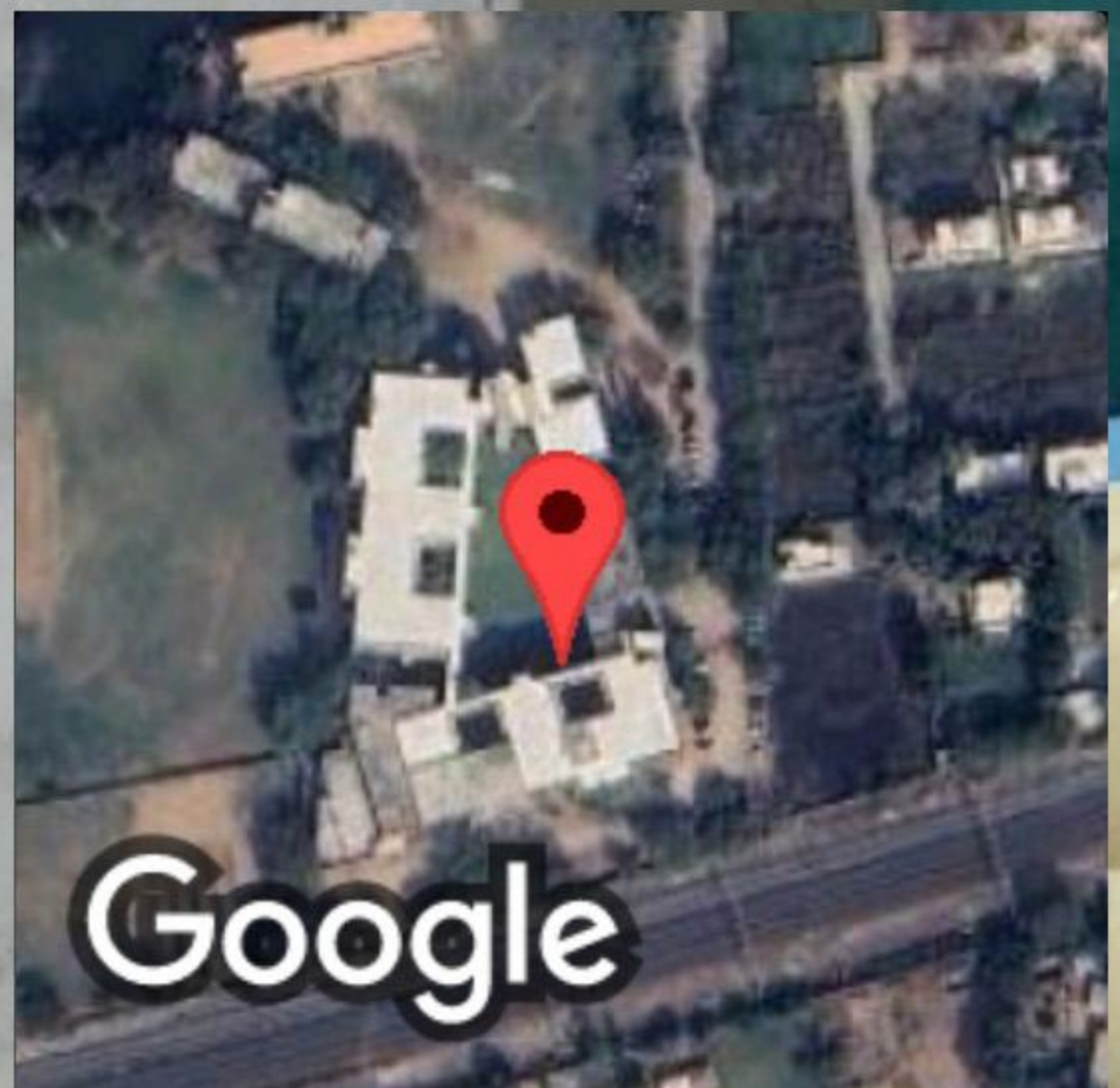
**Clearing** - Comprises of removal of all potentially pathogenic substance from root canal system.  
**Forming** - Establishment of specifically shaped cavity which performs dual role of three dimensional progressive access.  
**Sealing** - Sealing and creating apical preparation which will permit final obturation, instrumentation & material to fit inside.

**CAUSAL FACTS**

- Obtaining Easy Flow
- Avoid Transportation of Canal
- Avoid Foreman
- Seal Foreman possible

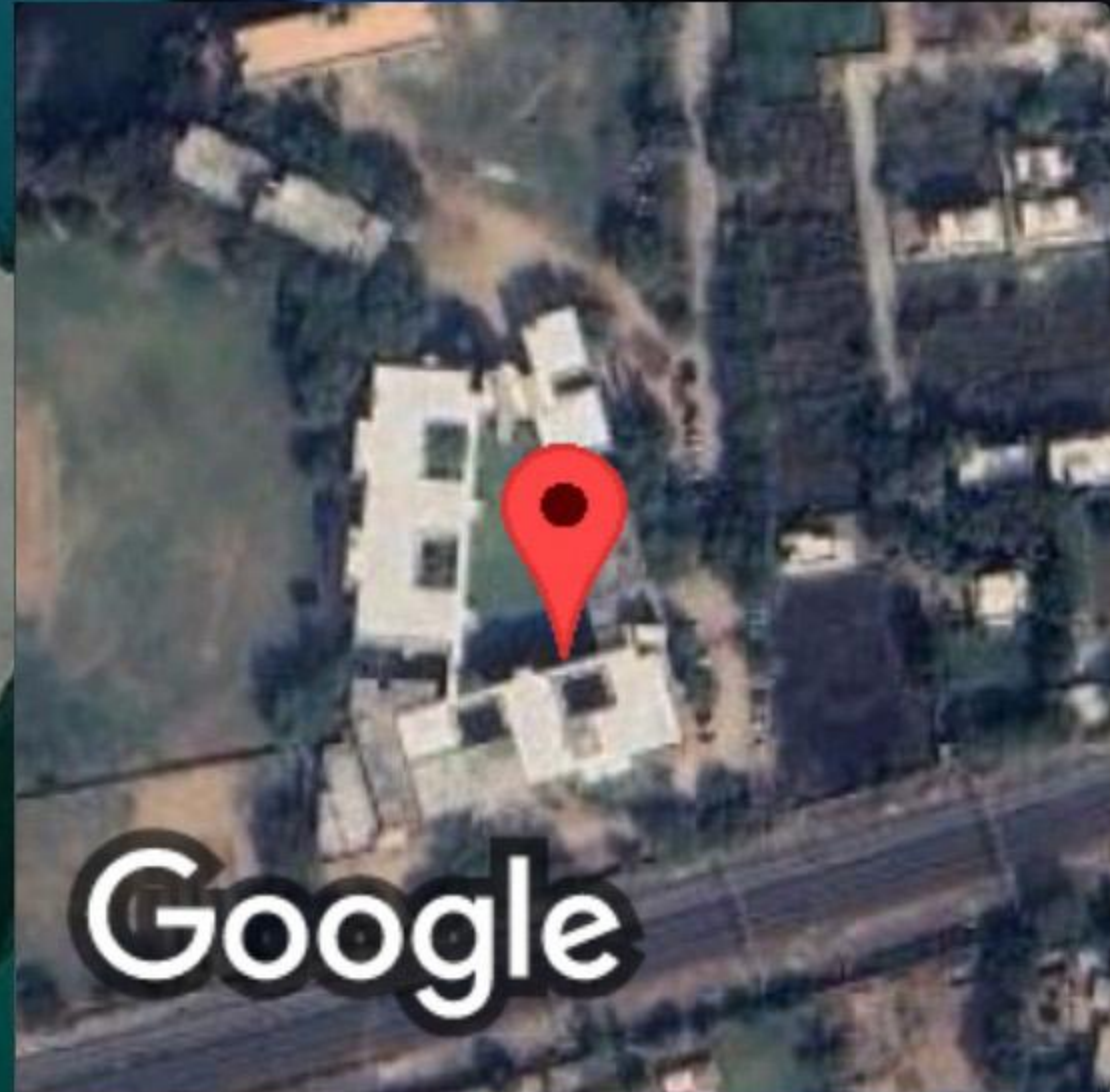
**STEP-BY-STEP METHOD**  
(Obtaining "Seal Root Canal Preparation")

Ahmedabad, Gujarat, India  
COLLEGE OF DENTAL SCIENCES AND RESEARCH CENTRE, Gujarat 380058, India  
Lat 23.03463  
Long 72.43601  
18/06/2019 11:50 AM GMT +05:30





**BIOMECHANICAL PREPARATION**  
Completion of removal of all grossly carious tissue  
Establishment of specifically shaped cavity preparation  
into lateral and lingual preparation which will  
be retained in the tooth  
**OBJECTIVES**  
1. Obtaining Easy Flow  
(Narrow Apically & Avoid Transportation of G.  
Wider Coronal)  
2. Keep the apical foramen  
as small as possible  
**STOP BACK TISSUES**  
Preparation of Root Canal System



Ahmedabad, Gujarat, India  
COLLEGE OF DENTAL SCIENCES AND RESEARCH CENTRE, Gujarat 380058, India  
Lat 23.03463  
Long 72.43601  
13/07/2019 11:40 AM GMT +05:30

GX-8000





Ahmedabad, Gujarat, India  
COLLEGE OF DENTAL SCIENCES AND RESEARCH CENTRE, Gujarat 380058, India  
Lat 23.03463  
Long 72.43601  
16/07/2019 11:45 AM GMT +05:30

