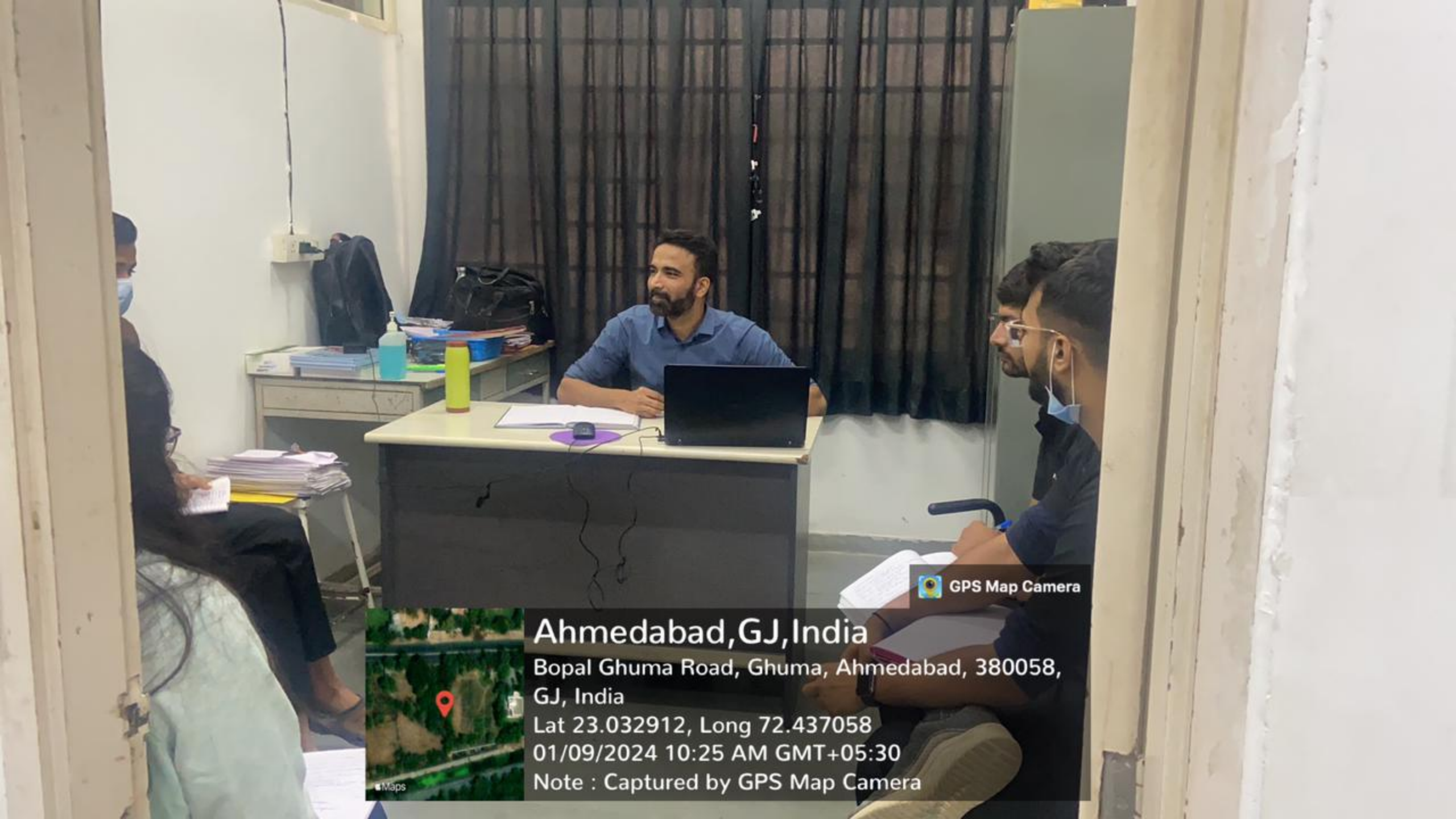

 GPS Map Camera



Ahmedabad, GJ, India
Bopal Ghuma Road, Ghuma, Ahmedabad, 380058,
GJ, India
Lat 23.032912, Long 72.437058
01/09/2024 10:25 AM GMT+05:30
Note : Captured by GPS Map Camera




GPS Map Camera




Ahmedabad, GJ, India
Bopal Ghuma Road, Bopal, Ahmedabad, 380058, GJ,
India
Lat 23.034103, Long 72.436673
01/10/2024 12:45 PM GMT+05:30
Note : Captured by GPS Map Camera




જીવતંત્ર 404
↓ $Vt + K$
જીવતંત્ર
↓
લોહિત Ca^{+2}
↓
પ્રોતોમોન Ca
↓
થ્રોમોન
↓
ક્લોટ -

 GPS Map Camera



Ahmedabad, GJ, India
Bopal Ghuma Road, Bopal, Ahmedabad, 380058, GJ, India
Lat 23.034106, Long 72.436671
01/11/2024 10:23 AM GMT+05:30
Note : Captured by GPS Map Camera




 GPS Map Camera



Ahmedabad, GJ, India
Bopal, Ahmedabad, 380058, GJ, India
Lat 23.034228, Long 72.437271
01/17/2024 10:19 AM GMT+05:30
Note : Captured by GPS Map Camera



GPS Map Camera



Ahmedabad, GJ, India

Bopal Ghuma Road, Bopal, Ahmedabad, 380058, GJ, India

Lat 23.034103, Long 72.436673

01/10/2024 12:45 PM GMT+05:30

Note : Captured by GPS Map Camera



GPS Map Camera



Ahmedabad, GJ, India
Bopal, Ahmedabad, 380058, GJ, India
Lat 23.034311, Long 72.436099
01/20/2024 12:51 PM GMT+05:30
Note : Captured by GPS Map Camera



GPS Map Camera



Ahmedabad, GJ, India
Bopal, Ahmedabad, 380058, GJ, India
Lat 23.034311, Long 72.436099
01/20/2024 12:51 PM GMT+05:30
Note : Captured by GPS Map Camera




Ahmedabad, GJ, India

Bopal, Ahmedabad, 380058, GJ, India

Lat 23.034320, Long 72.436129

01/20/2024 01:20 PM GMT+05:30

Note : Captured by GPS Map Camera

 GPS Map Camera



GPS Map Camera



Ahmedabad, GJ, India
Bopal, Ahmedabad, 380058, GJ, India
Lat 23.034305, Long 72.436161
01/20/2024 01:20 PM GMT+05:30
Note : Captured by GPS Map Camera

RED AND WHITE LESIONS OF ORAL CAVITY

WHITE LESION

IT IS A NON SPECIFIC TERM USED TO DESCRIBE ANY ABNORMAL AREA OF ORAL MUCOSA WHICH ON CLINICAL EXAMINATION APPEARS WHITER THAN THE SURROUNDING TISSUE, AND HAS GREATLY SLIGHTLY RAISED, BOUNDED OR UNBOUNDED SURFACES TEXTURE FROM ALMOST NORMAL TISSUE.

CLASSIFICATION

- Leukoplakia
- Leukoedema
- Leukoplakia
- Leukoedema
- Leukoplakia
- Leukoedema
- Leukoplakia
- Leukoedema
- Leukoplakia
- Leukoedema
- Leukoplakia
- Leukoedema

DISEASE OF PERIAPICAL TISSUES

Periapical abscess


Periapical abscess is a localized collection of pus that forms at the apex of a tooth root. It is caused by bacterial infection of the pulp space. The infection spreads through the root canal to the apex of the root, where it forms a pocket of pus. This pocket is surrounded by inflamed tissue, which forms a capsule. The capsule is made of fibrous tissue and contains a mass of pus. The pressure of the pus pushes against the surrounding tissue, causing pain and swelling. The abscess may spread to the surrounding soft tissue, causing a facial or lingual abscess. It may also spread to the bone, causing a periapical abscess.

U. G. CLINIC



GPS Map Camera

Ahmedabad, GJ, India
Bopal Ghuma Road, Ghuma, Ahmedabad, 380058,
GJ, India
Lat 23.033240, Long 72.437601
02/24/2024 11:54 AM GMT+05:30
Note : Captured by GPS Map Camera





GPS Map Camera



Ahmedabad, GJ, India

Bopal, Ahmedabad, 380058, GJ, India

Lat 23.034322, Long 72.436119

02/28/2024 02:15 PM GMT+05:30

Note : Captured by GPS Map Camera



GPS Map Camera



Ahmedabad, GJ, India

Bopal, Ahmedabad, 380058, GJ, India

Lat 23.034322, Long 72.436119

02/28/2024 02:15 PM GMT+05:30

Note : Captured by GPS Map Camera



U.G SECTION


LESIONS OF LIP

ANGULAR CHELITIS	TRAUMATIC UPPER LIP
ANGIOEDEMA	KERATOACANTHOMA
PRIMARY SYPHILIS	EROSIVE LICHEN
HERPES LABIALIS	CHEILITIS GLABRA

ORAL MANIFESTATIONS OF AIDS

PERFORATED LESIONS	PERFORATED LESIONS
PERFORATED LESIONS	PERFORATED LESIONS
PERFORATED LESIONS	PERFORATED LESIONS
PERFORATED LESIONS	PERFORATED LESIONS

GPS Map Camera



Ahmedabad, GJ, India
 Bopal, Ahmedabad, 380058, GJ, India
 Lat 23.034354, Long 72.436267
 03/06/2024 10:29 AM GMT+05:30
 Note : Captured by GPS Map Camera



U.G SECTION

LESIONS OF LIP
ANGULAR CHELITIS
TRAIUMATIC UPPER LIP
ANGIOEDEMA
EEMATOACANTHOMA
PRIMARY SYPHILIS
EROSIVE LICHEN
HERPES LABIALIS
CHELITIS GRANULOSA

ORAL MANIFESTATIONS OF AIDS
PERFORATED LESIONS

GPS Map Camera



Ahmedabad, GJ, India
Bopal, Ahmedabad, 380058, GJ, India
Lat 23.034321, Long 72.436277
03/06/2024 10:29 AM GMT+05:30
Note : Captured by GPS Map Camera



DISEASE
TYPICAL TISSUES

Hand hygiene poster with diagrams and text.

GPS Map Camera



Ahmedabad, GJ, India
Bopal, Ahmedabad, 380058, GJ, India
Lat 23.034345, Long 72.436086
03/07/2024 02:28 PM GMT+05:30
Note : Captured by GPS Map Camera




GPS Map Camera



Ahmedabad, GJ, India
Bopal, Ahmedabad, 380058, GJ, India
Lat 23.034335, Long 72.436158
03/11/2024 11:55 AM GMT+05:30
Note : Captured by GPS Map Camera



GPS Map Camera



Ahmedabad, GJ, India
Bopal, Ahmedabad, 380058, GJ, India
Lat 23.034335, Long 72.436158
03/11/2024 11:55 AM GMT+05:30
Note : Captured by GPS Map Camera



GPS Map Camera



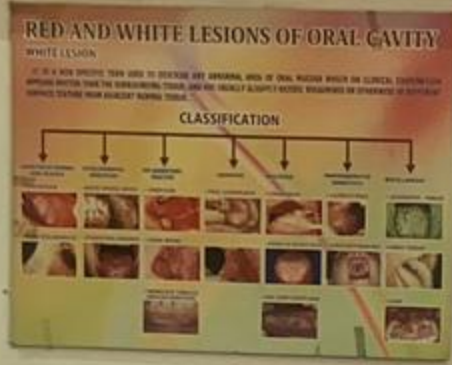
Ahmedabad, GJ, India

Bopal, Ahmedabad, 380058, GJ, India

Lat 23.034335, Long 72.436158

03/11/2024 11:55 AM GMT+05:30

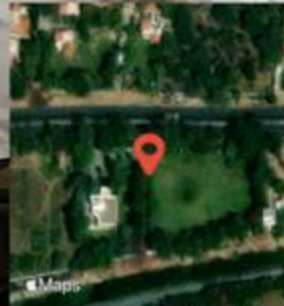
Note : Captured by GPS Map Camera



U. G. CLINIC



GPS Map Camera



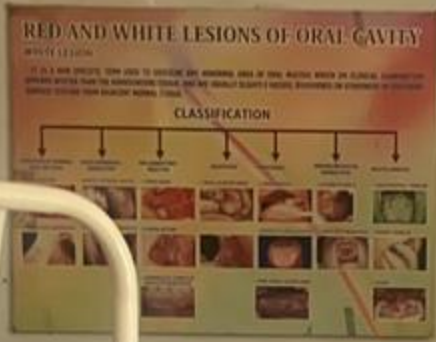Ahmedabad, GJ, India
Bopal Ghuma Road, Ghuma, Ahmedabad, 380058,
GJ, India
Lat 23.033147, Long 72.437957
03/13/2024 10:29 AM GMT+05:30
Note : Captured by GPS Map Camera



GPS Map Camera



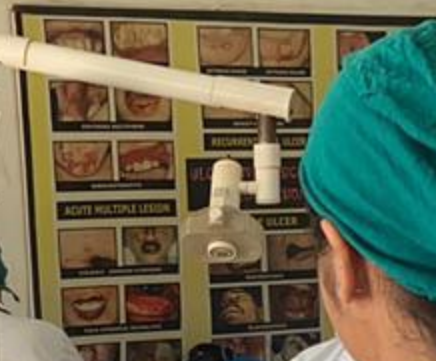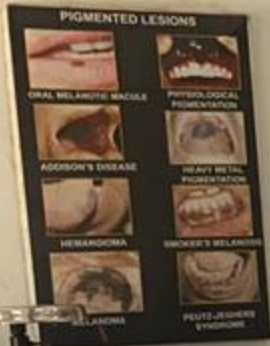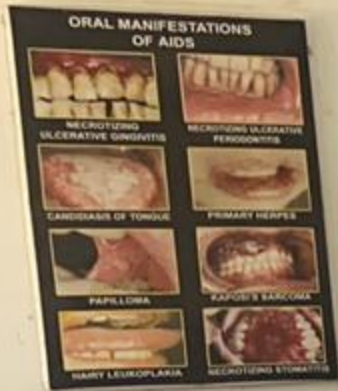
Ahmedabad, GJ, India
Bopal, Ahmedabad, 380058, GJ, India
Lat 23.034265, Long 72.436315
03/11/2024 11:55 AM GMT+05:30
Note : Captured by GPS Map Camera




GPS Map Camera



Ahmedabad, GJ, India
 Bopal Ghuma Road, Ghuma, Ahmedabad, 380058,
 GJ, India
 Lat 23.033059, Long 72.437743
 03/20/2024 11:23 AM GMT+05:30
 Note : Captured by GPS Map Camera




GPS Map Camera



Ahmedabad, GJ, India
Bopal, Ahmedabad, 380058, GJ, India
Lat 23.034404, Long 72.436240
03/27/2024 01:33 PM GMT+05:30
Note : Captured by GPS Map Camera



 GPS Map Camera



Ahmedabad, GJ, India

Bopal Ghuma Road, Ghuma, Ahmedabad, 380058,
GJ, India

Lat 23.033054, Long 72.437897

03/21/2024 01:49 PM GMT+05:30

Note : Captured by GPS Map Camera



U.G SECTION

ORAL MANIFESTATIONS
NECROTIC
ULCERATIVE
GANGRENOUS
LESIONS
PHYSIOLOGICAL
IDENTIFICATION
HEAVY METAL
POISONING

ACUTE MULTIPLE LESION
ULCERATIVE
BULLA

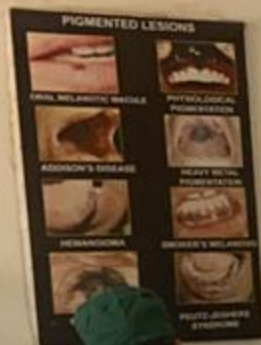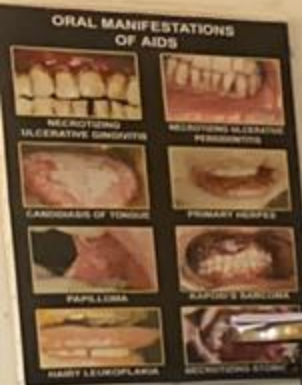RECURRENT ORAL
LESION

GPS Map Camera




Ahmedabad, GJ, India
Bopal, Ahmedabad, 380058, GJ, India
Lat 23.034378, Long 72.436315
03/27/2024 01:35 PM GMT+05:30
Note : Captured by GPS Map Camera

U.G SECTION



GPS Map Camera



Ahmedabad, GJ, India
Bopal, Ahmedabad, 380058, GJ, India
Lat 23.034285, Long 72.436119
03/28/2024 12:03 PM GMT+05:30
Note : Captured by GPS Map Camera

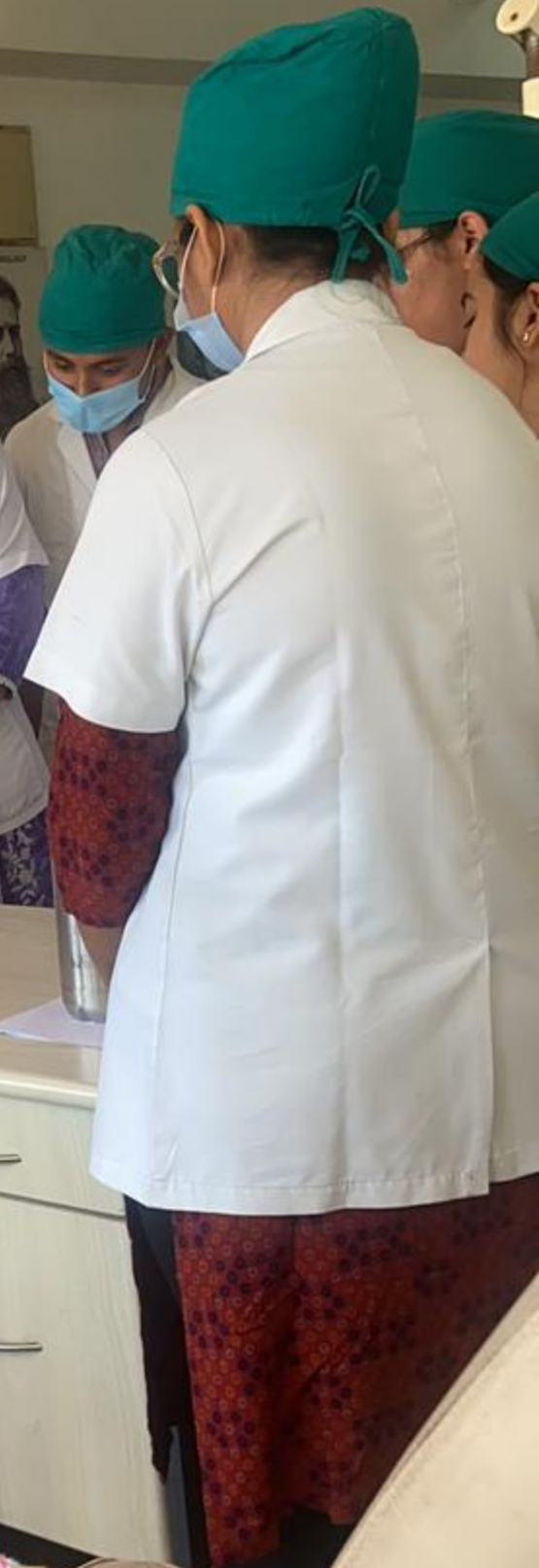
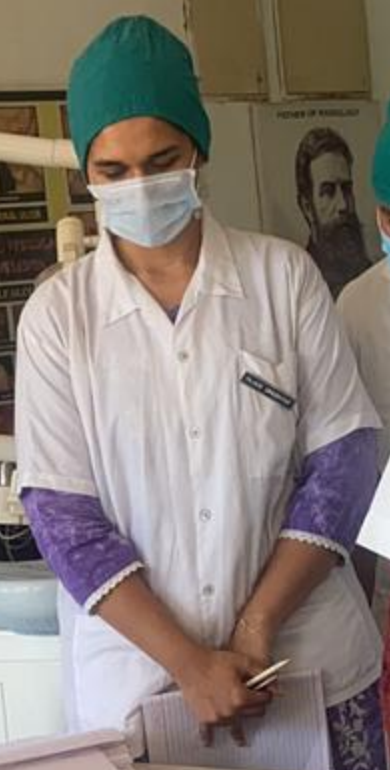
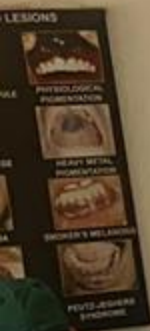GPS Map Camera



Ahmedabad, GJ, India
Bopal, Ahmedabad, 380058, GJ, India
Lat 23.034296, Long 72.436101
03/28/2024 12:03 PM GMT+05:30
Note : Captured by GPS Map Camera

CTION



GPS Map Camera

Ahmedabad, GJ, India

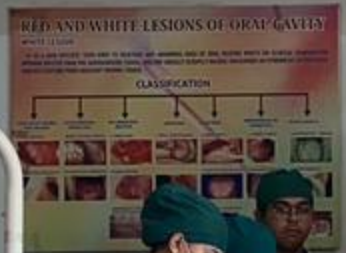
Bopal, Ahmedabad, 380058, GJ, India

Lat 23.034259, Long 72.436157

03/28/2024 12:03 PM GMT+05:30

Note : Captured by GPS Map Camera

Maps



GPS Map Camera

Ahmedabad, GJ, India

Bopal Ghuma Road, Ghuma, Ahmedabad, 380058,
GJ, India

Lat 23.033048, Long 72.437790

04/01/2024 10:27 AM GMT+05:30


Note : Captured by GPS Map Camera



Apple Maps



GPS Map Camera



Ahmedabad, GJ, India

Bopal, Ahmedabad, 380058, GJ, India

Lat 23.034385, Long 72.436172

09/11/2023 10:25 AM GMT+05:30

Note : Captured by GPS Map Camera



20

GPS Map Camera



Ahmedabad, GJ, India
Bopal, Ahmedabad, 380058, GJ, India
Lat 23.034385, Long 72.436172
09/11/2023 10:25 AM GMT+05:30
Note : Captured by GPS Map Camera




GPS Map Camera



Ahmedabad, GJ, India
Bopal, Ahmedabad, 380058, GJ, India
Lat 23.034385, Long 72.436172
09/11/2023 01:46 PM GMT+05:30
Note : Captured by GPS Map Camera



GPS Map Camera



Ahmedabad, GJ, India
Bopal, Ahmedabad, 380058, GJ, India
Lat 23.034385, Long 72.436172
09/11/2023 01:46 PM GMT+05:30
Note : Captured by GPS Map Camera




GPS Map Camera



Ahmedabad, GJ, India
Bopal, Ahmedabad, 380058, GJ, India
Lat 23.034385, Long 72.436172
09/11/2023 01:46 PM GMT+05:30
Note : Captured by GPS Map Camera



 GPS Map Camera

Ahmedabad, GJ, India

Bopal, Ahmedabad, 380058, GJ, India

Lat 23.034360, Long 72.436138

09/16/2023 12:07 PM GMT+05:30

Note : Captured by GPS Map Camera




Maps



Acute Radiation Sy
→ whole body exposure
1-2 -
2-4 - bone marrow →
4-7 -
7-15 -
>50 -

GPS Map Camera



Ahmedabad, GJ, India
Bopal, Ahmedabad, 380058, GJ, India
Lat 23.034360, Long 72.436138
09/16/2023 12:07 PM GMT+05:30
Note : Captured by GPS Map Camera



GPS Map Camera



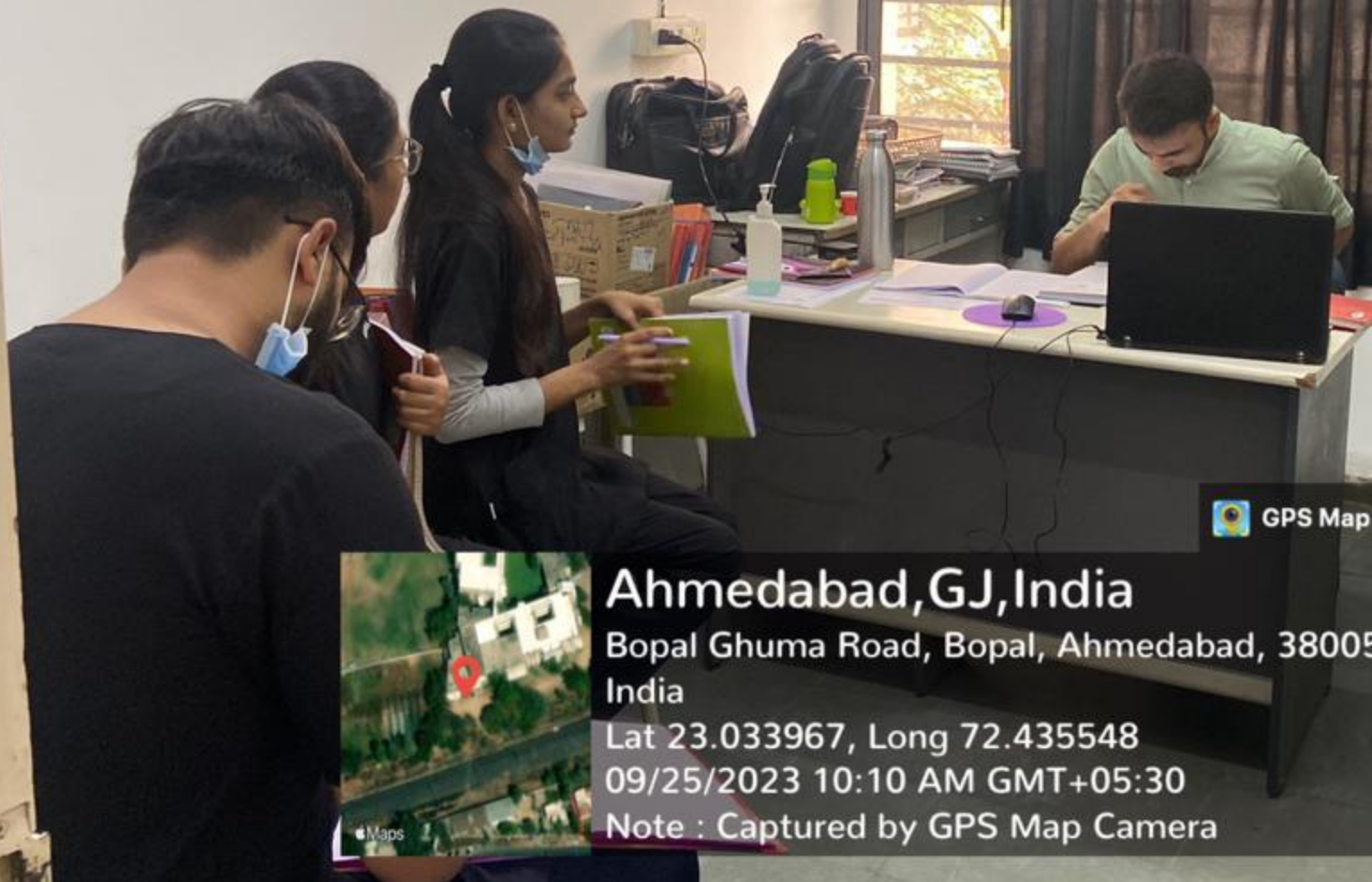Ahmedabad, GJ, India
Bopal, Ahmedabad, 380058, GJ, India
Lat 23.034360, Long 72.436138
09/16/2023 12:07 PM GMT+05:30
Note : Captured by GPS Map Camera





GPS Map Camera



Ahmedabad, GJ, India
Bopal, Ahmedabad, 380058, GJ, India
Lat 23.034360, Long 72.436138
09/20/2023 09:50 AM GMT+05:30
Note : Captured by GPS Map Camera



 GPS Map Camera



Ahmedabad, GJ, India

Bopal Ghuma Road, Bopal, Ahmedabad, 380058, GJ,
India

Lat 23.033967, Long 72.435548

09/25/2023 10:10 AM GMT+05:30

Note : Captured by GPS Map Camera

TREATMENT MODALITIES

Excision of the lesion	Fluoride therapy	Antibiotics	Antifungal agents	Photodynamic therapy	Surgical management
Fluoride varnish	Fluoride gel	Fluoride mouthwash	Fluoride toothpaste	Photodynamic therapy	Surgical management
Fluoride varnish	Fluoride gel	Fluoride mouthwash	Fluoride toothpaste	Photodynamic therapy	Surgical management

Department of Oral Medicine and Pathology
COLLEGE OF DENTAL SCIENCES & RESEARCH CENTRE

SELF ASSESSMENT FOR ORAL CANCER
EARLY STAGE ORAL CANCER IS OFTEN PAINLESS & GOES UNDETECTED

HOW TO SEE ?

Oral Medicine and Pathology
Department of Oral Medicine and Pathology
COLLEGE OF DENTAL SCIENCES & RESEARCH CENTRE

GPS Map Camera

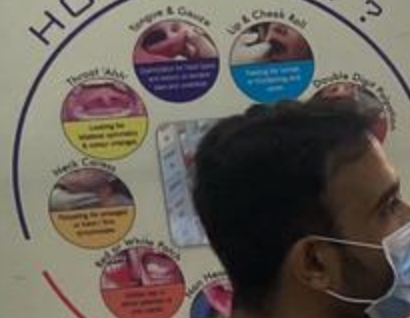Ahmedabad, GJ, India
Bopal Ghuma Road, Bopal, Ahmedabad, 380058, GJ, India
Lat 23.033299, Long 72.436756
09/25/2023 12:56 PM GMT+05:30
Note : Captured by GPS Map Camera

1.
2.
3.
4.
5.

SELF ASSESSMENT FOR ORAL CANCER

EARLY STAGE ORAL CANCER IS OFTEN PAINLESS & GOES UNDETECTED

HOW TO SEE



WHAT

TREATMENT MODALITIES

Elimination of risk factors	Parent counseling Advice to quit smoking
Antibiotics	8 courses, 1 course
Vitamins	Vitamin A, Vitamin C, Vitamin E, Vitamin K
Anti-neoplastic agents	Breastin, 5-Fluorouracil
Chemopreventive agents	Curcumin, Green tea
Immunomodulators	Interferon, A, Interferon, B
Photodynamic therapy	Conventional, Photodynamic, Laser
Surgical management	Conventional, Laser, Cryotherapy, Cryosurgery

Department of Oral Medicine and Radiology
SCIENTIFIC & RESEARCH CENTRE

A man in a light green shirt and blue face mask is speaking to a group of medical students. The students are wearing white lab coats and green surgical caps. One student in the foreground is looking at a small object held by the man. The scene is set in a room with a large window in the background.

Ahmedabad, GJ, India

Bopal Ghuma Road, Bopal, Ahmedabad, 380058, GJ, India

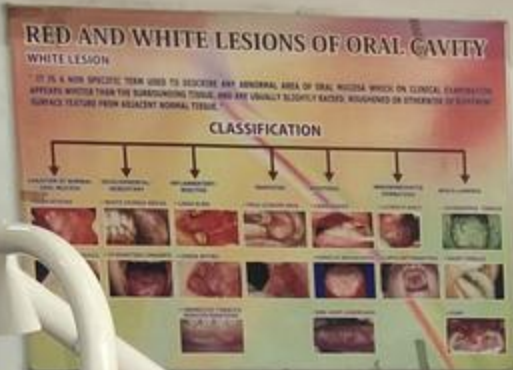
Lat 23.033202, Long 72.437153

09/25/2023 12:56 PM GMT+05:30

Note : Captured by GPS Map Camera

GPS Map Camera





U. G. CLINIC



GPS Map Camera



Ahmedabad, GJ, India
Bopal, Ahmedabad, 380058, GJ, India
Lat 23.034362, Long 72.436140
09/28/2023 10:38 AM GMT+05:30
Note : Captured by GPS Map Camera



PG SECTION

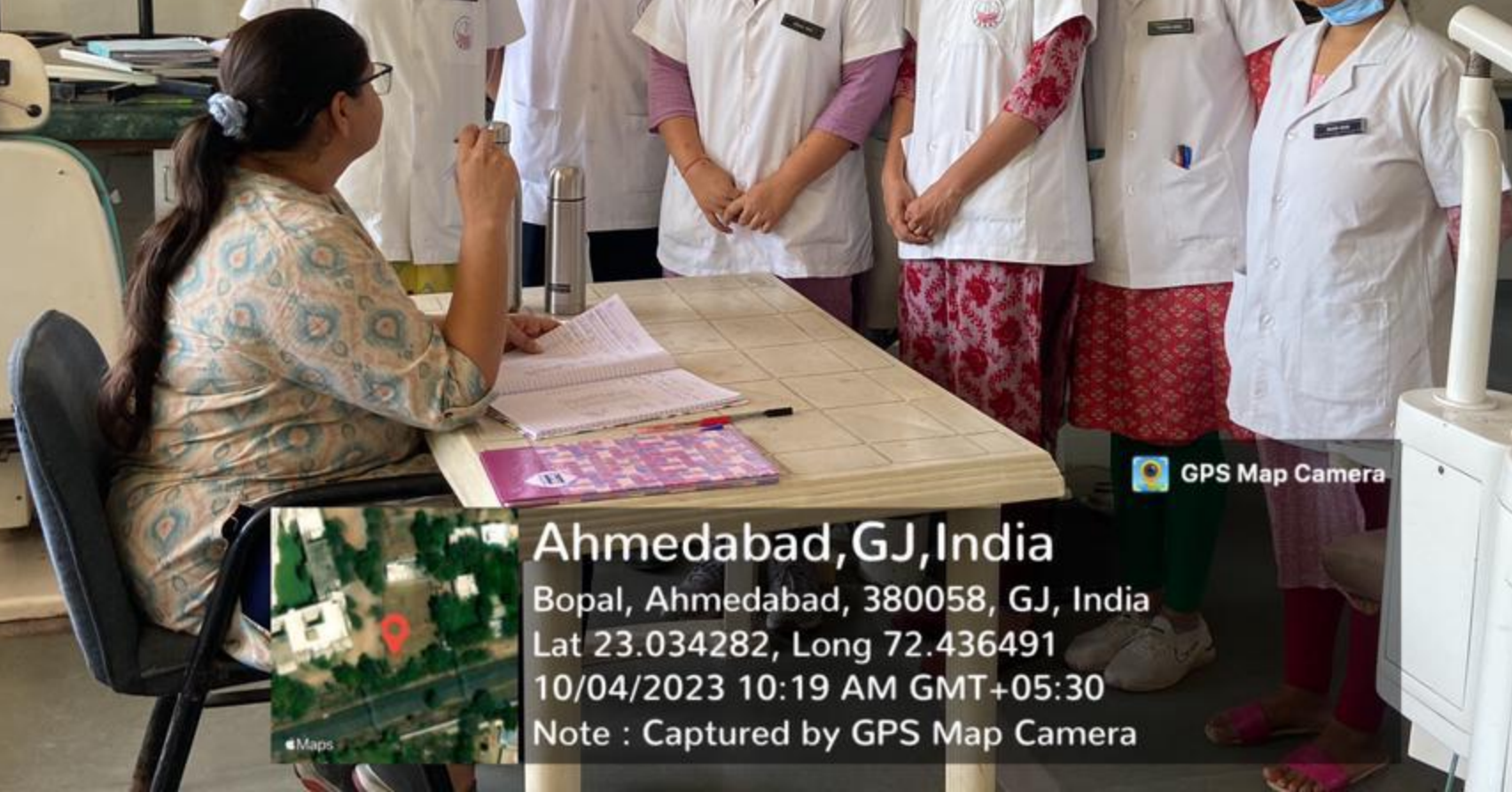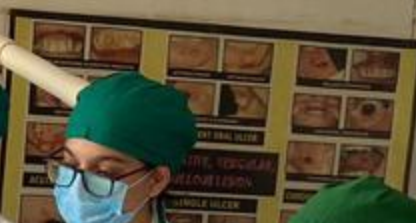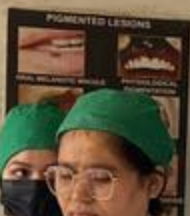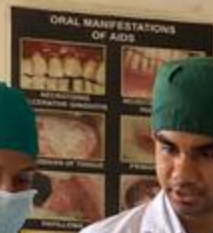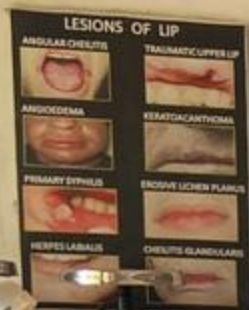CASE HISTORY PROGRAM

GPS Map Camera



Ahmedabad, GJ, India
Bopal, Ahmedabad, 380058, GJ, India
Lat 23.034362, Long 72.436140
10/07/2023 01:16 PM GMT+05:30
Note : Captured by GPS Map Camera

U.G SECTION



GPS Map Camera



Ahmedabad, GJ, India
Bopal, Ahmedabad, 380058, GJ, India
Lat 23.034282, Long 72.436491
10/04/2023 10:19 AM GMT+05:30
Note : Captured by GPS Map Camera



U.G SECTION

LESIONS OF LIP
ANGULAR CHEILITIS
TRICHOICLONIA
ANGIOEDEMA
KERATOCANTH
PRIMARY SYPHILIS
HERPESLABIALIS

ORAL MANIFESTATIONS OF AIDS
PERFORATED PALATE
OROPHARYNGEAL CANDIDIASIS
KOPPEL'S LEUKOPLAKIA
OROPHARYNGEAL CARCINOMA

PIGMENTED LESIONS
MELANOTIC NEVI
MELANOMA
MELANOCYTOUS NEVI
MELANOCYTOUS NEVI
MELANOCYTOUS NEVI

RECURRENT ORAL ULCER
MUCOCYSTIC LESIONS
MUCOCYSTIC LESIONS
MUCOCYSTIC LESIONS
MUCOCYSTIC LESIONS
MUCOCYSTIC LESIONS



GPS Map Camera

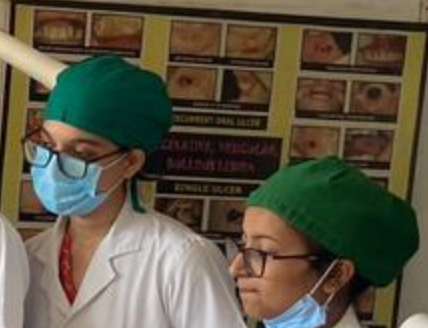
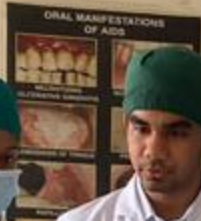
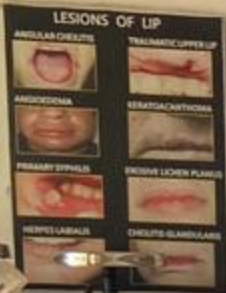Ahmedabad, GJ, India
Bopal, Ahmedabad, 380058, GJ, India
Lat 23.034295, Long 72.436518
10/04/2023 10:19 AM GMT+05:30
Note : Captured by GPS Map Camera

Maps



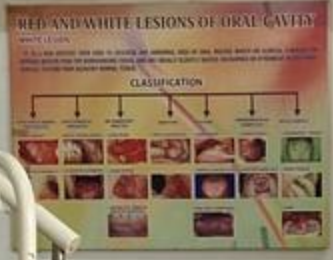
U.G SECTION



GPS Map Camera



Ahmedabad, GJ, India
Bopal, Ahmedabad, 380058, GJ, India
Lat 23.034295, Long 72.436518
10/04/2023 10:19 AM GMT+05:30
Note : Captured by GPS Map Camera




GPS Map Camera



Ahmedabad, GJ, India
Bopal, Ahmedabad, 380058, GJ, India
Lat 23.034362, Long 72.436140
10/06/2023 12:34 PM GMT+05:30
Note : Captured by GPS Map Camera



 GPS Map Camera

Ahmedabad, GJ, India

Bopal Ghuma Road, Bopal, Ahmedabad, 380058, GJ,
India

Lat 23.033821, Long 72.436512

10/07/2023 01:54 PM GMT+05:30

Note : Captured by GPS Map Camera



Apple Maps



GPS Map Camera



Ahmedabad, GJ, India
Bopal, Ahmedabad, 380058, GJ, India
Lat 23.034362, Long 72.436140
10/04/2023 10:43 AM GMT+05:30
Note : Captured by GPS Map Camera



GPS Map Camera


Ahmedabad, GJ, India

Bopal Ghuma Road, Bopal, Ahmedabad, 380058, GJ, India

Lat 23.033337, Long 72.436680


10/10/2023 11:39 AM GMT+05:30

Note : Captured by GPS Map Camera



Maps



 GPS Map Camera

Ahmedabad, GJ, India

Bopal Ghuma Road, Bopal, Ahmedabad, 380058, GJ, India

Lat 23.033171, Long 72.436743

10/10/2023 12:11 PM GMT+05:30

Note : Captured by GPS Map Camera



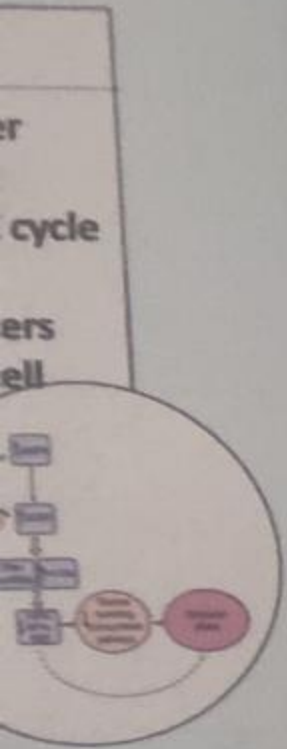
Maps



GPS Map Camera



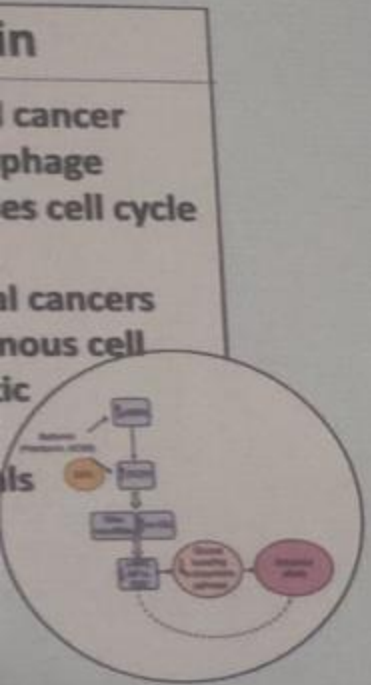
Ahmedabad, GJ, India
Bopal, Ahmedabad, 380058, GJ, India
Lat 23.033193, Long 72.436729
10/12/2023 12:56 PM GMT+05:30
Note : Captured by GPS Map Camera



GPS Map Camera



Ahmedabad, GJ, India
Bopal, Ahmedabad, 380058, GJ, India
Lat 23.034362, Long 72.436140
10/13/2023 10:44 AM GMT+05:30
Note : Captured by GPS Map Camera



GPS Map Camera



Ahmedabad, GJ, India
Bopal, Ahmedabad, 380058, GJ, India
Lat 23.034362, Long 72.436140
10/13/2023 10:44 AM GMT+05:30
Note : Captured by GPS Map Camera




GPS Map Camera



Ahmedabad, GJ, India
Bopal Ghuma Road, Bopal, Ahmedabad, 380058, GJ, India
Lat 23.033879, Long 72.436218
10/17/2023 10:27 AM GMT+05:30
Note : Captured by GPS Map Camera



 GPS Map Camera


Ahmedabad, GJ, India

Bopal Ghuma Road, Bopal, Ahmedabad, 380058, GJ,
India

Lat 23.033879, Long 72.436218

10/17/2023 10:27 AM GMT+05:30

Note : Captured by GPS Map Camera





GPS Map Camera



Ahmedabad, GJ, India
Bopal, Ahmedabad, 380058, GJ, India
Lat 23.034443, Long 72.436458
10/23/2023 01:40 PM GMT+05:30
Note : Captured by GPS Map Camera



ORAL MANIFESTATIONS OF AIDS

TRICHOMALACIA	PERFORATING GINGIVITIS
OROPHARYNGEAL CANDIDIASIS	ACUTE PERIODONTITIS
ORAL LEUKOPLAKIA	ORAL CARCINOMA
HERPES SIMPLEX	HERPES ZOSTER
ERYTHROBLASTIC INFILTRATION	ANGIOEDEMA
STOMATITIS	PERIOSTOMATITIS
PERIODONTITIS	PERIOIMMUNITIS
PERIOIMMUNITIS	PERIOIMMUNITIS

PIGMENTED LESIONS

ORAL MELANOTIC NEVUS	ORAL MELANOMA
ADDISON'S DISEASE	ORAL MELANOMA
ORAL MELANOMA	ORAL MELANOMA
ORAL MELANOMA	ORAL MELANOMA
ORAL MELANOMA	ORAL MELANOMA
ORAL MELANOMA	ORAL MELANOMA
ORAL MELANOMA	ORAL MELANOMA
ORAL MELANOMA	ORAL MELANOMA

GPS Map Camera

Ahmedabad, GJ, India
Bopal, Ahmedabad, 380058, GJ, India
Lat 23.034444, Long 72.436457
10/23/2023 01:40 PM GMT+05:30
Note : Captured by GPS Map Camera





GPS Map Camera

Ahmedabad, GJ, India

Bopal Ghuma Road, Bopal, Ahmedabad, 380058, GJ, India

Lat 23.033737, Long 72.437493


10/25/2023 12:40 PM GMT+05:30

Note : Captured by GPS Map Camera



Apple Maps




 GPS Map Camera



Ahmedabad, GJ, India
Bopal, Ahmedabad, 380058, GJ, India
Lat 23.034348, Long 72.436162
10/25/2023 12:41 PM GMT+05:30
Note : Captured by GPS Map Camera



 GPS Map Camera



Ahmedabad, GJ, India
Bopal Ghuma Road, Bopal, Ahmedabad, 380058, GJ,
India
Lat 23.033999, Long 72.437050
10/25/2023 12:40 PM GMT+05:30
Note : Captured by GPS Map Camera



GPS Map Camera



Ahmedabad, GJ, India

Bopal, Ahmedabad, 380058, GJ, India

Lat 23.033969, Long 72.436661

10/25/2023 02:16 PM GMT+05:30

Note : Captured by GPS Map Camera



GPS Map Camera



Ahmedabad, GJ, India

Bopal, Ahmedabad, 380058, GJ, India

Lat 23.034367, Long 72.436275

10/25/2023 12:41 PM GMT+05:30

Note : Captured by GPS Map Camera




GPS Map Camera



Ahmedabad, GJ, India
Bopal, Ahmedabad, 380058, GJ, India
Lat 23.034255, Long 72.435790
10/26/2023 12:47 PM GMT+05:30
Note : Captured by GPS Map Camera



 GPS Map Camera



Ahmedabad, GJ, India
Bopal, Ahmedabad, 380058, GJ, India
Lat 23.034334, Long 72.436189
10/30/2023 10:49 AM GMT+05:30
Note : Captured by GPS Map Camera



GPS Map Camera

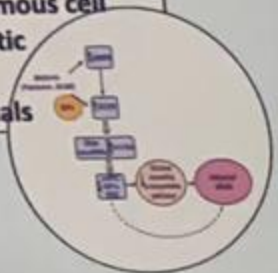

Ahmedabad, GJ, India
Bopal, Ahmedabad, 380058, GJ, India
Lat 23.034249, Long 72.435773
10/26/2023 12:47 PM GMT+05:30
Note : Captured by GPS Map Camera

Metformin

Metformin treated cancer
modulate macrophage
infiltration and causes cell cycle

Metformin can be used in oral cancers
especially Oral squamous cell
carcinomas in diabetic
patients
under clinical trials



Technology
CENTRE



Ahmedabad, GJ, India

Bopal, Ahmedabad, 380058, GJ, India

Lat 23.034334, Long 72.436189

11/01/2023 11:01 AM GMT+05:30

Note : Captured by GPS Map Camera

GPS Map Camera

Department of Oral Medicine and Radiology
COLLEGE OF DENTAL SCIENCES AND RESEARCH CENTRE

NACT

- Drugs like osimertinib, nivolumab and cetuximab can be used to reduce surgical margins and decrease recurrence rates.
- Can be used in oral cancers especially squamous cell carcinoma
- Undergoing clinical trials

EGFR

- Anti-EGFR antibodies (most commonly monoclonal antibodies) and small molecule tyrosine kinase target EGFR
- Commonly used in treating Oral squamous cell Carcinomas
- Under clinical trials

Metformin


- Metformin treated cancer cells modulate macrophage polarization and causes cell cycle arrest
- Can be used in oral cancers especially Oral squamous cell carcinomas in diabetic patients
- Under clinical trials



Ahmedabad, GJ, India
Bopal, Ahmedabad, 380058, GJ, India
Lat 23.034334, Long 72.436189
11/01/2023 11:01 AM GMT+05:30
Note : Captured by GPS Map Camera

GPS Map Camera



 GPS Map Camera

Ahmedabad, GJ, India

Bopal Ghuma Road, Bopal, Ahmedabad, 380058, GJ,
India

Lat 23.033870, Long 72.436738

10/31/2023 02:09 PM GMT+05:30

Note : Captured by GPS Map Camera





GPS Map Camera



Ahmedabad, GJ, India
Bopal, Ahmedabad, 380058, GJ, India
Lat 23.034627, Long 72.436099
11/08/2023 02:11 PM GMT+05:30
Note : Captured by GPS Map Camera



GPS Map Camera



Ahmedabad, GJ, India

Bopal, Ahmedabad, 380058, GJ, India

Lat 23.034334, Long 72.436189

11/07/2023 10:39 AM GMT+05:30

Note : Captured by GPS Map Camera




GPS Map Camera



Ahmedabad, GJ, India
Bopal, Ahmedabad, 380058, GJ, India
Lat 23.034610, Long 72.436177
11/08/2023 02:11 PM GMT+05:30
Note : Captured by GPS Map Camera



 GPS Map Camera



Ahmedabad, GJ, India
Bopal, Ahmedabad, 380058, GJ, India
Lat 23.034610, Long 72.436085
11/08/2023 02:11 PM GMT+05:30
Note : Captured by GPS Map Camera



WORLD RADIOLOGY DAY

GPS Map Camera



Ahmedabad, GJ, India
Bopal, Ahmedabad, 380058, GJ, India
Lat 23.034613, Long 72.436190
11/08/2023 02:12 PM GMT+05:30
Note : Captured by GPS Map Camera



GPS Map Camera



Ahmedabad, GJ, India
Bopal, Ahmedabad, 380058, GJ, India
Lat 23.034613, Long 72.436193
11/08/2023 02:12 PM GMT+05:30
Note : Captured by GPS Map Camera



GPS Map Camera



Ahmedabad, GJ, India
Bopal, Ahmedabad, 380058, GJ, India
Lat 23.034595, Long 72.436178
11/08/2023 02:11 PM GMT+05:30
Note : Captured by GPS Map Camera



GPS Map Camera



Ahmedabad, GJ, India

Bopal, Ahmedabad, 380058, GJ, India

Lat 23.034587, Long 72.436184

11/08/2023 02:13 PM GMT+05:30

Note : Captured by GPS Map Camera

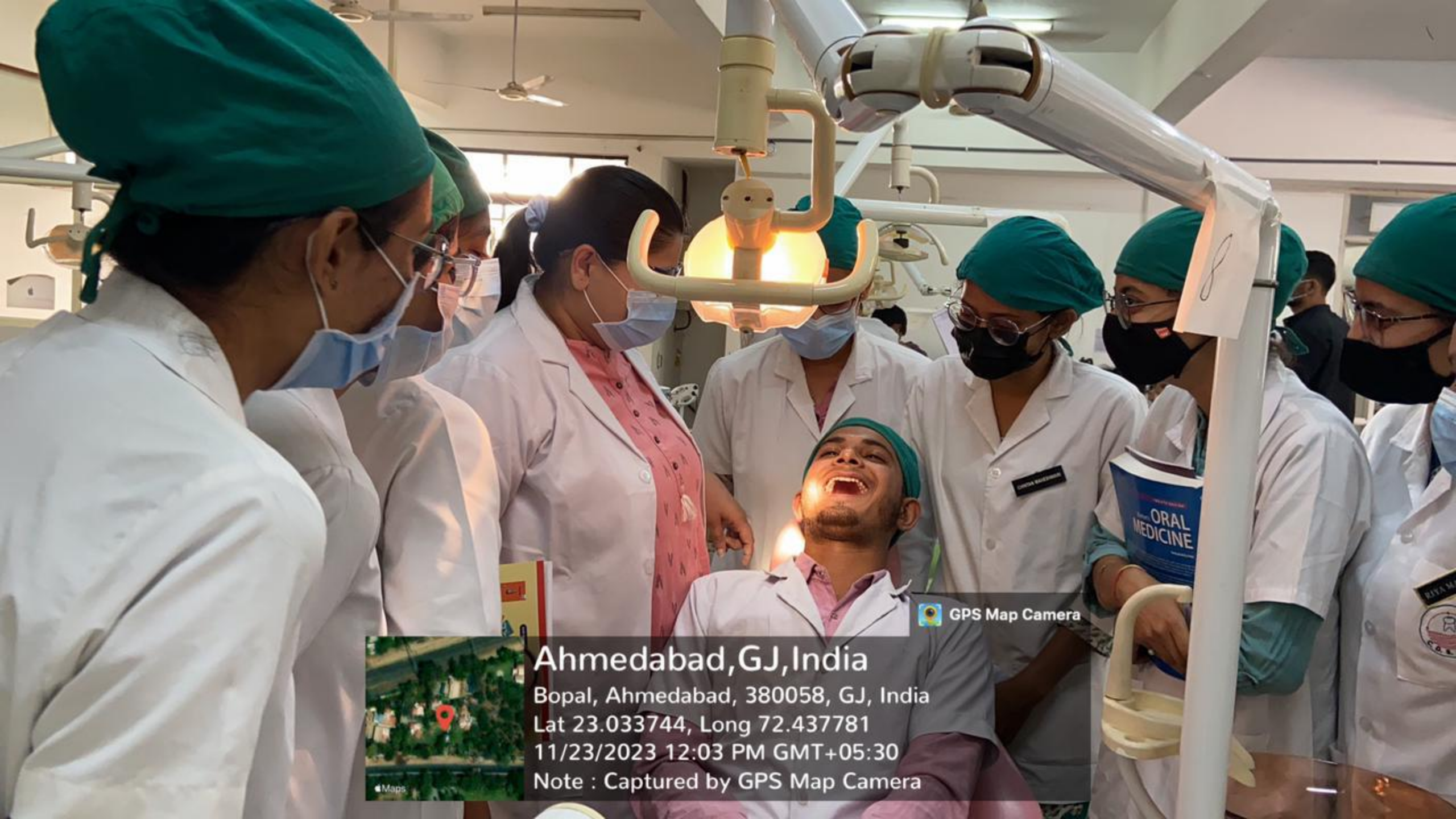

WORLD RADIOLOGY DAY
11/08/2023

GPS Map Camera



Ahmedabad, GJ, India
Bopal, Ahmedabad, 380058, GJ, India
Lat 23.034621, Long 72.436191
11/08/2023 02:12 PM GMT+05:30
Note : Captured by GPS Map Camera



GPS Map Camera



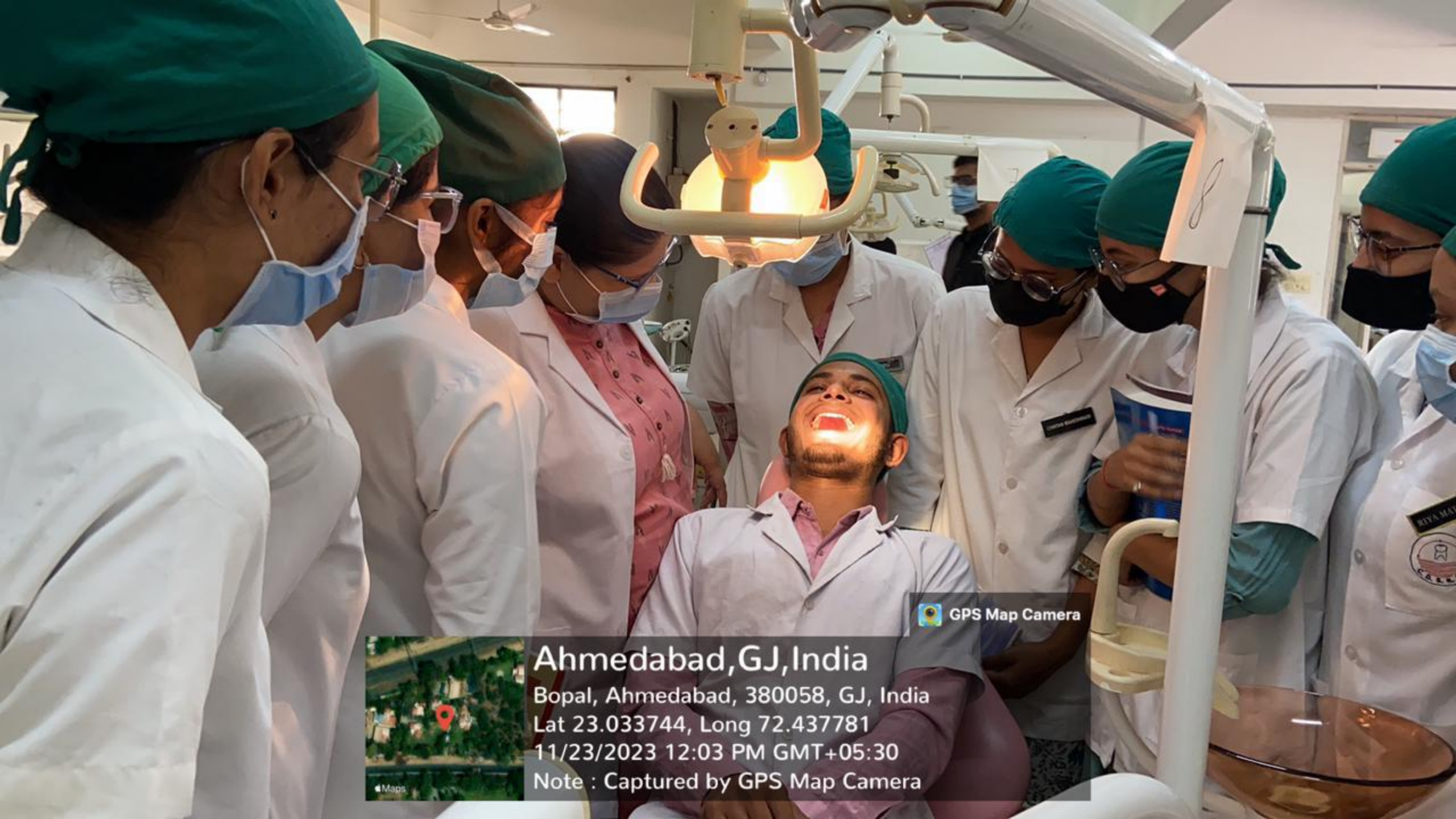Ahmedabad, GJ, India
Bopal, Ahmedabad, 380058, GJ, India
Lat 23.033744, Long 72.437781
11/23/2023 12:03 PM GMT+05:30
Note : Captured by GPS Map Camera



GPS Map Camera



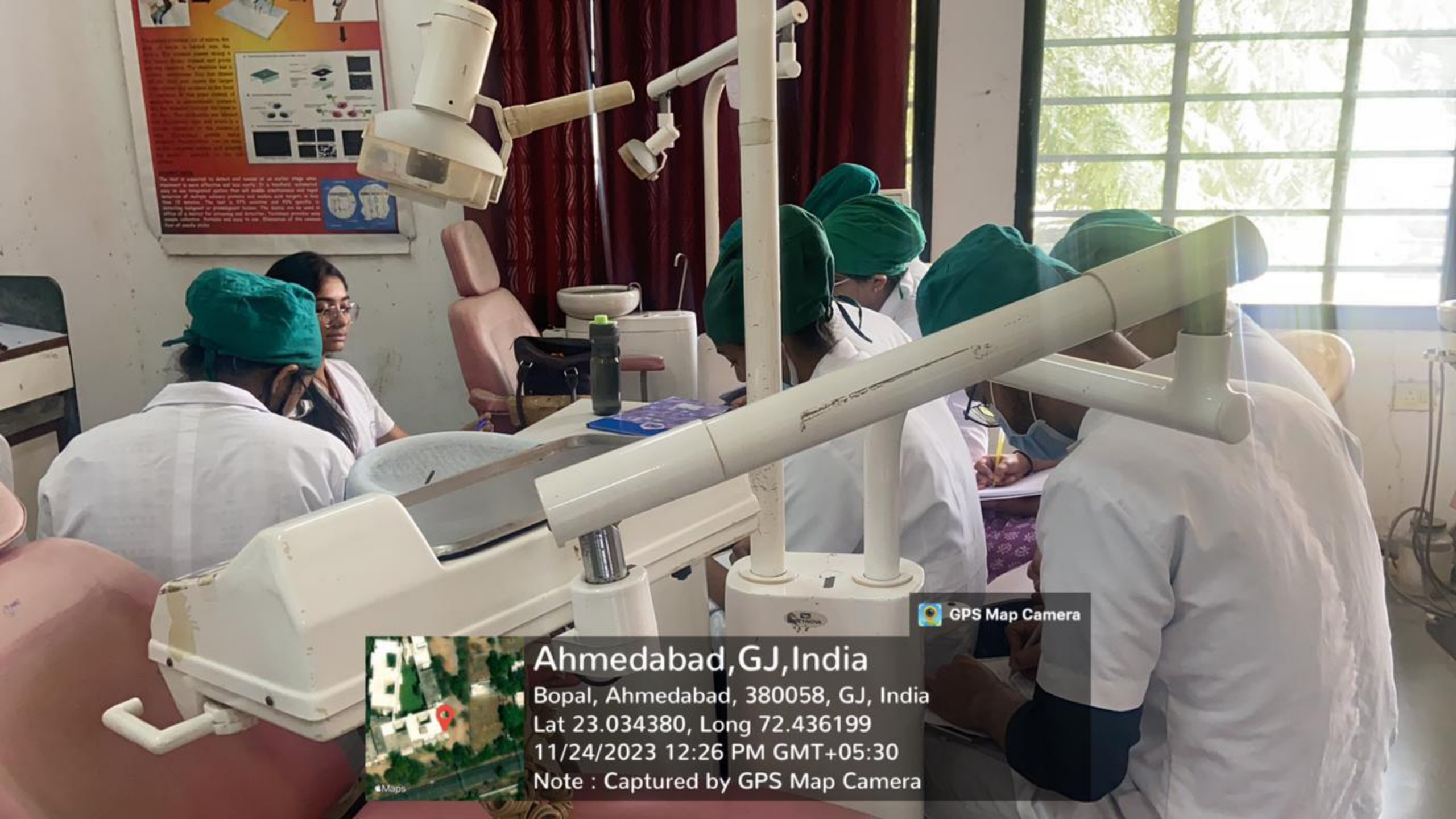Ahmedabad, GJ, India
Bopal, Ahmedabad, 380058, GJ, India
Lat 23.034600, Long 72.436170
11/08/2023 02:13 PM GMT+05:30
Note : Captured by GPS Map Camera




GPS Map Camera



Ahmedabad, GJ, India
Bopal, Ahmedabad, 380058, GJ, India
Lat 23.033744, Long 72.437781
11/23/2023 12:03 PM GMT+05:30
Note : Captured by GPS Map Camera



The most common use of water in the dental office is for rinsing. The water should be clean, soft, and free of chlorine. The chlorine can irritate the oral tissues. The water should be filtered through a charcoal filter. The filtered water should be used for rinsing. The water should be changed frequently. The water should be at a temperature of 68-72 degrees Fahrenheit. The water should be tested for lead. The water should be tested for copper. The water should be tested for iron. The water should be tested for manganese. The water should be tested for calcium. The water should be tested for magnesium. The water should be tested for sodium. The water should be tested for potassium. The water should be tested for chloride. The water should be tested for sulfate. The water should be tested for nitrate. The water should be tested for nitrite. The water should be tested for ammonia. The water should be tested for nitrite. The water should be tested for nitrate. The water should be tested for nitrite. The water should be tested for ammonia. The water should be tested for nitrite. The water should be tested for nitrate. The water should be tested for nitrite. The water should be tested for ammonia.

 GPS Map Camera



Ahmedabad, GJ, India
 Bopal, Ahmedabad, 380058, GJ, India
 Lat 23.034380, Long 72.436199
 11/24/2023 12:26 PM GMT+05:30
 Note : Captured by GPS Map Camera




GPS Map Camera



Ahmedabad, GJ, India
Bopal, Ahmedabad, 380058, GJ, India
Lat 23.033744, Long 72.437781
11/23/2023 12:03 PM GMT+05:30
Note : Captured by GPS Map Camera



 GPS Map Camera



Ahmedabad, GJ, India
Bopal, Ahmedabad, 380058, GJ, India
Lat 23.034383, Long 72.436202
11/29/2023 10:52 AM GMT+05:30
Note : Captured by GPS Map Camera



GPS Map Camera



Ahmedabad, GJ, India

Bopal, Ahmedabad, 380058, GJ, India

Lat 23.034387, Long 72.436197

12/04/2023 09:50 AM GMT+05:30

Note : Captured by GPS Map Camera



GPS Map Camera



Ahmedabad, GJ, India


Bopal, Ahmedabad, 380058, GJ, India

Lat 23.034383, Long 72.436202

11/29/2023 12:08 PM GMT+05:30

Note : Captured by GPS Map Camera



 GPS Map Camera



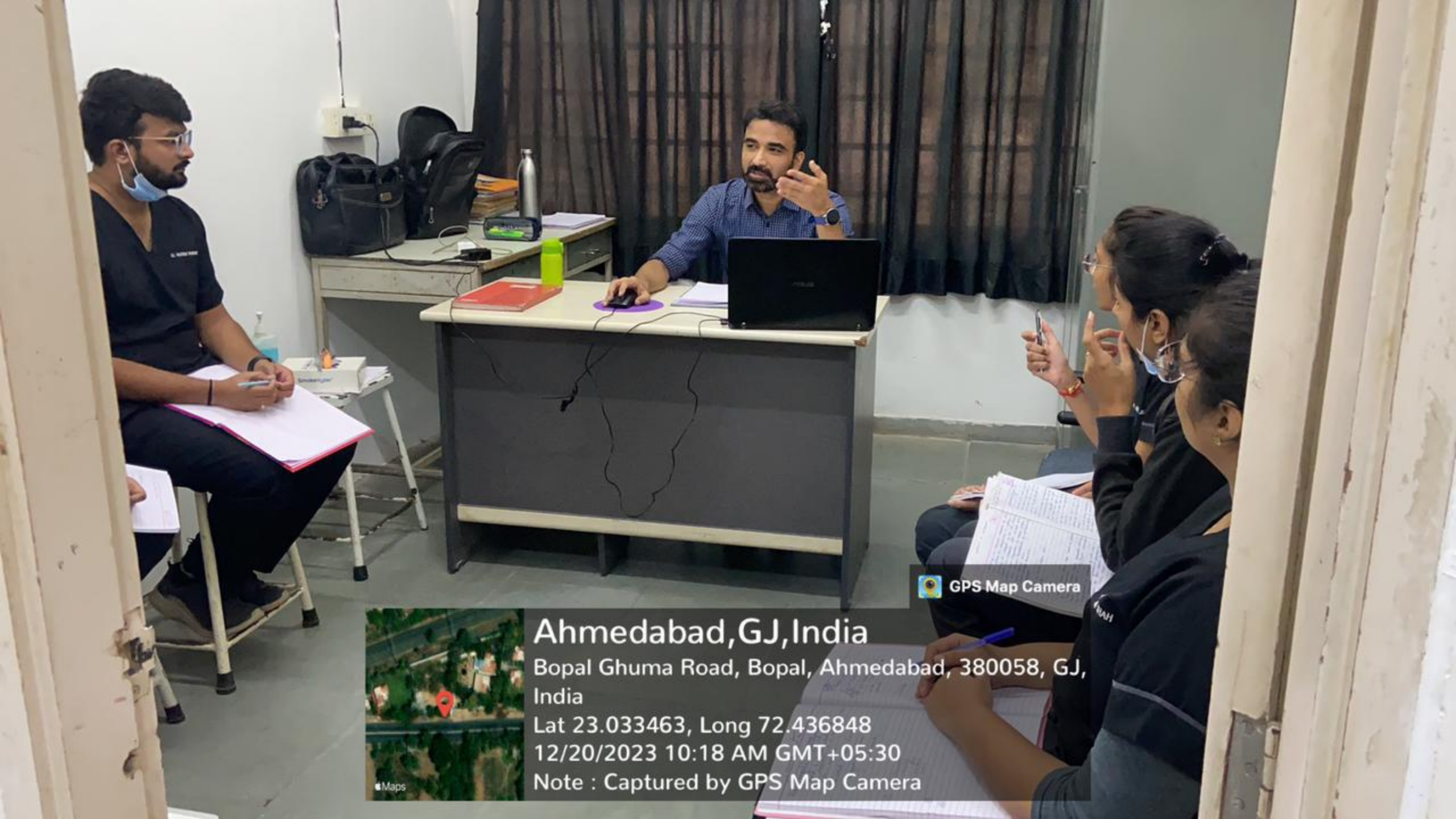Ahmedabad, GJ, India

Bopal Ghuma Road, Bopal, Ahmedabad, 380058, GJ, India

Lat 23.033240, Long 72.437311

12/05/2023 10:49 AM GMT+05:30

Note : Captured by GPS Map Camera



GPS Map Camera



Ahmedabad, GJ, India

Bopal Ghuma Road, Bopal, Ahmedabad, 380058, GJ, India

Lat 23.033463, Long 72.436848

12/20/2023 10:18 AM GMT+05:30

Note : Captured by GPS Map Camera

MANAGEMENT OF LEUKOPLAKIA

PLAKIA

HIGH RISK (>2cm, heterogenous, tongue, floor of mouth)

BIOPSY

Moderate to severe dysplasia

Excision With 5 mm margins

Department of Oral Medicine and Radiology
COLLEGE OF DENTAL SCIENCES & RESEARCH CENTRE

QUIT HABITS

NICOTINE REPLACEMENT THERAPY

CAROTENOIDS

VITAMIN C

GREEN TEA

IMIQIMOD cream, 5%

PHOTODYNAMIC THERAPY

TREATMENT MODALITIES

Elimination of risk factors	Patient counselling Advice to quit
Antioxidants	B-carotene
Vitamins	Retinoids Fenretinone Vitamin E
Anti-neoplastic agents	Bleomycin
Chemo-preventive agents	Curcumin
Immunomodulators	Interferon- α

SELF ASSESSMENT FOR ORAL CANCER

EARLY STAGE ORAL CANCER IS OFTEN PAINLESS & GOES UNDETECTED

HOW TO SEE

WHAT TO

Throat Area
Tongue & Gums
Lip & Cheek Kull
Double
Nail Cavity
Warts
Non-Healing Ulcers
Reddish Area

Department of Oral Medicine and Radiology
COLLEGE OF DENTAL SCIENCES & RESEARCH CENTRE



GPS Map Camera



Ahmedabad, GJ, India
 Bopal Ghuma Road, Bopal, Ahmedabad, 380058, GJ, India
 Lat 23.033647, Long 72.437056
 12/19/2023 11:41 AM GMT+05:30
 Note : Captured by GPS Map Camera



GPS Map Camera


Ahmedabad, GJ, India

Bopal Ghuma Road, Bopal, Ahmedabad, 380058, GJ, India

Lat 23.033310, Long 72.437612

12/20/2023 11:55 AM GMT+05:30


Note : Captured by GPS Map Camera



Apple Maps



GPS Map Camera



Ahmedabad, GJ, India
Bopal, Ahmedabad, 380058, GJ, India
Lat 23.034299, Long 72.435903
12/22/2023 12:13 PM GMT+05:30
Note : Captured by GPS Map Camera




GPS Map Camera

Ahmedabad, GJ, India
Bopal, Ahmedabad, 380058, GJ, India
Lat 23.034321, Long 72.436083
12/22/2023 12:13 PM GMT+05:30
Note : Captured by GPS Map Camera






GPS Map Camera



Ahmedabad, GJ, India
Bopal, Ahmedabad, 380058, GJ, India
Lat 23.034279, Long 72.436050
12/22/2023 12:13 PM GMT+05:30
Note : Captured by GPS Map Camera




 GPS Map Camera



Ahmedabad, GJ, India
Bopal Ghuma Road, Ghuma, Ahmedabad, 380058,
GJ, India
Lat 23.032912, Long 72.437058
01/09/2024 10:25 AM GMT+05:30
Note : Captured by GPS Map Camera



GPS Map Camera



Ahmedabad, GJ, India

Bopal Ghuma Road, Bopal, Ahmedabad, 380058, GJ, India


Lat 23.034103, Long 72.436673

01/10/2024 12:45 PM GMT+05:30

Note : Captured by GPS Map Camera



GPS Map Camera



Ahmedabad, GJ, India


Bopal Ghuma Road, Bopal, Ahmedabad, 380058, GJ, India

Lat 23.034103, Long 72.436673

01/10/2024 12:45 PM GMT+05:30

Note : Captured by GPS Map Camera



 GPS Map Camera




Ahmedabad, GJ, India
Bopal, Ahmedabad, 380058, GJ, India
Lat 23.034228, Long 72.437271
01/17/2024 10:19 AM GMT+05:30
Note : Captured by GPS Map Camera



જીવતંત્ર ૫૯૯
↓ $Vt \cdot K$
જીવતંત્ર ૫
↓
લોહિત Ca^{+2}
↓
પ્રોટોમોન Ca
↓
થ્રોમોન
↓
clot -

GPS Map Camera



Ahmedabad, GJ, India
Bopal Ghuma Road, Bopal, Ahmedabad, 380058, GJ, India
Lat 23.034106, Long 72.436671
01/11/2024 10:23 AM GMT+05:30
Note : Captured by GPS Map Camera